

## VU Research Portal

### **Posterior spinal surgery for adolescent idiopathic scoliosis does not induce compensatory increases in distal adjacent segment motion: a prospective gait analysis study**

Holewijn, Roderick M.; Kingma, Idsart; de Kleuver, Marinus; Keijsers, Noël L.W.

**published in**

Spine Journal

2018

**DOI (link to publisher)**

[10.1016/j.spinee.2018.05.010](https://doi.org/10.1016/j.spinee.2018.05.010)

**document version**

Publisher's PDF, also known as Version of record

**document license**

Article 25fa Dutch Copyright Act

[Link to publication in VU Research Portal](#)

**citation for published version (APA)**

Holewijn, R. M., Kingma, I., de Kleuver, M., & Keijsers, N. L. W. (2018). Posterior spinal surgery for adolescent idiopathic scoliosis does not induce compensatory increases in distal adjacent segment motion: a prospective gait analysis study. *Spine Journal*, 18(12), 2213-2219. <https://doi.org/10.1016/j.spinee.2018.05.010>

**General rights**

Copyright and moral rights for the publications made accessible in the public portal are retained by the authors and/or other copyright owners and it is a condition of accessing publications that users recognise and abide by the legal requirements associated with these rights.

- Users may download and print one copy of any publication from the public portal for the purpose of private study or research.
- You may not further distribute the material or use it for any profit-making activity or commercial gain
- You may freely distribute the URL identifying the publication in the public portal

**Take down policy**

If you believe that this document breaches copyright please contact us providing details, and we will remove access to the work immediately and investigate your claim.

**E-mail address:**

[vuresearchportal.ub@vu.nl](mailto:vuresearchportal.ub@vu.nl)

Clinical Study

# Posterior spinal surgery for adolescent idiopathic scoliosis does not induce compensatory increases in distal adjacent segment motion: a prospective gait analysis study

Roderick M. Holewijn, MD<sup>a,\*</sup>, Idsart Kingma, PhD<sup>b</sup>, Marinus de Kleuver, MD, PhD<sup>c</sup>,  
Noël L.W. Keijsers, PhD<sup>d</sup>

<sup>a</sup>Department of Orthopedic Surgery, VU University Medical Center, Amsterdam Movement Sciences, De Boelelaan 1117, Amsterdam, 1081 HV, The Netherlands

<sup>b</sup>Faculty of Behavioural and Movement Sciences, Vrije Universiteit Amsterdam, Amsterdam Movement Sciences, De Boelelaan 1105, Amsterdam, 1081 HV, The Netherlands

<sup>c</sup>Department of Orthopedic Surgery, Radboud University Medical Center, Mailbox 9101, 6500 HB, Nijmegen, The Netherlands

<sup>d</sup>Sint Maartenskliniek Research, Sint Maartenskliniek, Mailbox 9011, 6500 GM, Ubbergen, The Netherlands

Received 23 November 2017; revised 17 April 2018; accepted 1 May 2018

## Abstract

**BACKGROUND CONTEXT:** Patients with adolescent idiopathic scoliosis (AIS) perform surprisingly well after spinal correction and fusion. It was previously hypothesized that, during gait, certain mechanisms compensate for the loss in spinal motion. Still, previous studies could not identify such compensatory mechanisms in the lower body.

**PURPOSE:** This study aims to test the hypothesis of a compensatory increased motion of the distal unfused part of the spine during gait after posterior spinal correction and fusion.

**STUDY:** This is a prospective gait study.

**PATIENTS AND METHODS:** Twelve patients with AIS were included. Sets of three VICON skin markers were used to measure the 3D motion of the proximal part of the fusion in relation to the pelvis (PFP) and the distal part of the fusion in relation to the pelvis (DFP). By doing so, PFP represents the motion of the fused and unfused parts of the spine, and DFP represents the motion of the unfused part of the spine. Measurements were performed preoperatively and 3 and 12 months after posterior spinal correction and fusion.

**RESULTS:** Surgery resulted in a decrease in PFP transversal plane range of motion (ROM) (8.3° vs. 5.9°,  $p=.006$ ). No compensatory increase in the ROM of DFP could be identified. Actually, DFP transversal plane ROM also decreased (8.2° vs. 5.6°,  $p=.019$ ). No improvement over time was observed when comparing the 3- and 12-month postoperative measurements.

**CONCLUSIONS:** The hypothesis of a compensatory increase in motion of the distal unfused segments after spinal fusion for AIS is a much researched and controversial topic. This study is the first to study this hypothesis in such detail during gait and could not demonstrate such increase. © 2018 Elsevier Inc. All rights reserved.

**Keywords:** Adjacent segment degeneration; Adjacent segment motion; Adolescent idiopathic scoliosis; Gait analysis; Spinal fusion; Spinal motion

FDA device/drug status: Not applicable.

Author disclosures: **RMH:** Nothing to disclose. **IK:** Nothing to disclose.

**MK:** Speaking and/or Teaching Arrangements: DePuy Spine (B), Medtronic (B, Paid directly to institution), outside the submitted work. **NLWK:** Nothing to disclose.

The disclosure key can be found on the Table of Contents and at [www.TheSpineJournalOnline.com](http://www.TheSpineJournalOnline.com).

Marinus de Kleuver was a board member at SRS and Chairman of the Knowledge Forum Deformity at AOSpine.

\* Corresponding author. Department of Orthopedic Surgery, VU University Medical Center, Amsterdam Movement Sciences, De Boelelaan 1117, Amsterdam, 1081 HV, The Netherlands. Tel.: 0031 (0)20 7777777.

E-mail address: [rm.holewijn@vumc.nl](mailto:rm.holewijn@vumc.nl) (R.M. Holewijn)

## EVIDENCE & METHODS

### Context

It is commonly assumed that following fusion for AIS, patients compensate by increasing motion at distal adjacent segments. The authors assessed this assumption via gait analysis.

### Contribution

They found no increase in motion at distal adjacent segments and, indeed, a decrease in motion.

### Implications

The limitations are covered by the authors—a small number of patients and concerns over skin marker accuracy. That said, the findings are interesting and, if true (TBD), raise interesting questions. In what other ways might these patients “compensate” biomechanically? Or does normal function have a wide “safety zone” such that compensation is not required for it? Or is the measurement technique used simply the wrong tool to assess the situation at the adjacent levels?

This research represents (1) the apparent motion of the spine was tested by skin markers, not the spine itself. The reliability of this wasn't described unless I missed it, and (2) the results are early at just 3 and 12 months. Witness that BOTH the proximal and distal spines showed diminished motion. They reflect only the motion during the recovery phase and thus may not be predictive at all regarding the long-term effect of fusion.

## Introduction

Adolescent idiopathic scoliosis (AIS) is a complex three-dimensional (3D) spinal deformity characterized by a curvature in the frontal plane, a rotation in the transverse plane, and deviations in the sagittal plane. AIS is the most common type of spinal deformity in adolescents, and patients with severe curvatures are treated with surgical correction and long spinal fusion [1,2].

Surprisingly, despite the invasive surgery accompanied by the reduced mobility of the spine, the effect of surgery on overall daily physical activity is, although statistically significant, relatively small [3]. More specifically, gait is an important part of daily physical activity. Previous studies on gait in surgically treated patients with AIS report a decrease in the overall range of motion (ROM) of the thorax in relation to the pelvis but only minimal changes in lower limb kinematics after surgery [4–6]. Possibly, there are mechanisms at play during gait that compensate for the decreased spinal mobility.

It can be hypothesized that patients with AIS express mechanisms during gait that compensate for this decreased spinal motion. Our group has previously analyzed gait at increasing and, thus, more challenging walking speeds, requiring increased spinal mobility, to highlight and thus identify these

possible mechanisms [4]. Surprisingly, no such mechanisms were found in the upper or lower body. It is important to highlight that the abovementioned and previous gait analysis studies on surgically treated patients with AIS were performed using the trunk as a single body segment [4–6]. This approach lacks the opportunity to study local spinal kinematic changes during gait.

Possibly, the mechanisms that compensate for the stiffer spine after surgery are present in the unfused spinal segments. Previous studies have already demonstrated that during gait, different spinal regions show significant differences in motion patterns [7,8]. Looking more closely to the individual spinal segments (ie, fused vs. unfused) would provide more insights into why patients with AIS show such good recovery after invasive spinal fusion surgery. Furthermore, there is an ongoing discussion on whether adjacent spinal segment degeneration occurs after spinal fusion. It has been hypothesized that an increased (compensatory) motion of the unfused segments plays a causative role by inducing increased stress to the adjacent unfused intervertebral discs, but there is an increasing body of evidence that contradicts this hypothesis [9,10]. Data on local spine kinematics, rather than treating the spine as a single body segment, could provide a better understanding of the role of compensatory spine motions in postoperative recovery and aid in the discussion on adjacent segment degeneration.

The goal of the present study was to analyze the effect of posterior spinal correction and fusion on the motion of the distal unfused part of the spine. It was hypothesized that, during gait, the unfused segment shows an increase in ROM to compensate for the loss of ROM of the fused segment. Additionally, the present study analyzed the postoperative recovery by comparing short (3 months) and midterm (12 months) follow-up measurements.

## Patients and methods

### Study population

Ethical approval was obtained from the Independent Review Board Nijmegen (IRBN2010026). All participants and parents or guardians signed an informed consent before the study activities.

The study population consisted of female patients with AIS between 12 and 18 years old. The subjects did not suffer from any other disorders that could alter the gait pattern (ie, no neurologic or musculoskeletal disorders), had no history of spinal surgery, and did not suffer from cognitive disorders. A total of 12 patients with an age of  $15.2 \pm 1.7$  (mean  $\pm$  standard deviation) years at surgery were included. The mean preoperative Cobb angle was  $59 \pm 11^\circ$ , and at 3 and 12 months postoperatively, this was reduced to  $25 \pm 5^\circ$  and  $26 \pm 5^\circ$ , respectively. On average  $9 \pm 2$  spinal levels were fused during surgery. A detailed description of the individual patient characteristics and radiographic parameters is presented in [Tables 1 and 2](#).

All patients underwent posterior instrumented spinal fusion surgery. The surgery was performed by two experienced orthopedic surgeons who specialized in spine surgery. A pedicle

Table 1  
Patient characteristics

	Age at surgery (y)	Lenke type	UIV	LIV	Fused levels
1	12.0	1B	T4	T12	8
2	14.7	1B	T4	T12	8
3	14.9	3C	T3	L3	13
4	15.4	1A	T4	T12	8
5	15.6	2A	T6	L2	8
6	18.5	3C	T4	L3	11
7	16.1	3C	T3	L2	11
8	12.6	2A	T3	L1	10
9	16.5	1B	T5	T12	7
10	14.7	3C	T5	L3	10
11	15.9	2A	T3	T12	9
12	15.5	1A	T5	L1	8

UIV, upper instrumented vertebra; LIV, lower instrumented vertebra.

screw-based instrumentation was performed (Universal Spine System; Synthes, Oberdorf, Switzerland) was used for spinal instrumentation. All procedures were performed with intra-operative neuromonitoring.

#### Data collection

All subjects walked barefoot on a treadmill (Bonte BV, Zwolle, The Netherlands), wearing shorts and a running top to ensure that markers were placed directly on the skin. To limit any deviations between measurements, a single gait researcher experienced with palpation of the anatomical references placed all skin markers during each measurement. During approximately 2 minutes, the subjects were allowed to walk at 0.45 m/s to get familiar with treadmill walking. Subsequently, a walking trial of at least 45 seconds was performed at a comfortable walking speed of 1.35 m/s.

The subjects had a total of 40 markers on their body, of which 23 were placed on standardized positions on the upper body and the lower extremities according to the Plug-in-Gait model (VICON, Yarnnton, Oxfordshire, United Kingdom) (Table 3). The other 17 markers were placed on the spinal process and on both sides of the spine (Table 3, Fig. 1) in a pattern based on a validation in earlier studies [11,12]. The marker movements were registered by a 10-camera 3D motion capture video system VICON (VICON, Oxford Metrics, Yarnnton, Oxfordshire, United Kingdom) positioned around the treadmill at a sample rate of 100 Hz. Each trial was afterward labeled frame-by-frame to minimize technical errors

Table 2  
Radiographic parameters

	Measurement 1	Measurement 2	Measurement 3
Cobb	57.1±12.1	25.8±6.9	25.8±4.8
Pelvic tilt	6.9±8.0	7.4±5.5	11.0±9.2
Pelvic incidence	50.3±13.4	44.8±12.0	50.2±18.0
Sacral slope	43.7±9.6	37.4±8.2	39.4±10.6
Lumbar lordosis	57.8±8.0	55.8±9.4	57.0±15.5
Thoracic kyphosis	18.9±9.5	24.7±6.8	22.0±6.0

Measurement 1: preoperatively, Measurement 2: 3 months postoperatively, Measurement 3: 12 months postoperatively. Results are expressed in degrees, mean±standard deviation.

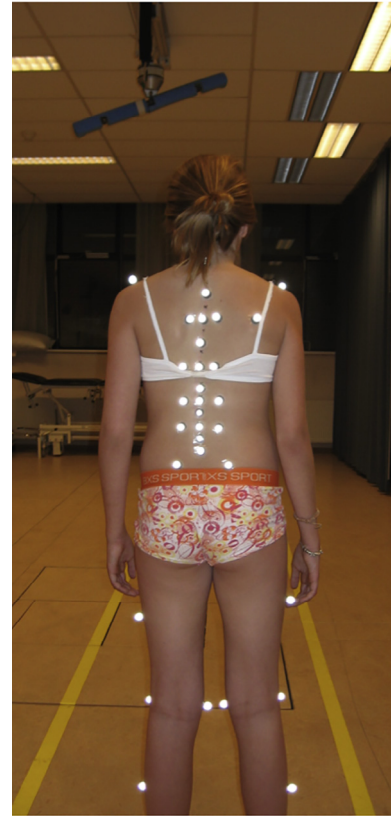


Fig. 1. Posterior view of the skin marker configuration.

and to ensure the quality of each trial. The labeled markers and the Plug-in-Gait model were used for the 3D modeling in VICON. Measurements were performed preoperatively and 3 and 12 months postoperatively.

#### Data analysis

The 3D position of the markers was filtered with a fourth-order low-pass Butterworth filter with a cutoff frequency of

Table 3  
Skin markers

Segment	Marker position	
Thorax	C7, T10	
	Articulation acromion-clavicle*	
	Articulation clavicle-sternum	
	Xiphoid	
Spine	Midclavicle right (antisymmetry marker)	
	T3, T5L, T5M, T5R, T7, T10L, T10R, T12, L1L, L1M, L1R, L2, L3L, L3M, L3R, L4, and L5	
	Pelvis	Anterior superior iliac spine and posterior superior iliac spine 2×
		Leg
	Articulation genus lateral 2×	
Foot	Tibia lateral side 2×	
	Lateral malleoli 2×	
	Heel 2×	
	Second metatarsal 2×	

M, middle, L, left side, R, right side.

\* Concave and convex sides.

5 Hz. Heel strikes were detected upon the anteroposterior direction of the right heel marker. A heel strike was defined as the instant when the right heel marker was as far as possible to the front. The middle 25 steps were taken to avoid any start-up and to stop irregularities.

The angles of the analyzed segments were all normalized to a heel strike-to-heel strike step cycle. Based on the middle 25 steps, a mean curve was calculated for a step cycle. From these mean curves, the ROM was calculated. The ROM during gait was calculated in the frontal, sagittal, and transversal planes by subtracting the minimal angle from the maximal angle.

To analyze the effect of the surgery on spinal motion, 3D motions during gait were measured on the proximal and the distal parts of the fused spine, and the ROM of these segments was expressed in the pelvic axis system. Spinal segment motion was described using Euler decomposition of the spine orientation relative to the pelvis, in following the order: sagittal plane (flexion or extension), frontal plane (lateral bending), and transversal plane (axial rotation), which is consistent with International Society of Biomechanics recommendations [13]. By doing so, the ROM of the markers on the proximal part of the fusion in relation to the pelvis (PFP) represented the motion of the fused and unfused parts of the spine. The ROM of the markers on the distal part of the fusion in relation to the pelvis (DFP) represented the motion of the unfused part of the spine. Thus, an increase in the ROM of DFP after surgery indicates a compensatory increase in the motion of the unfused spinal segments.

For the two analyzed segments (PFP and DFP), a subset of three spinal markers forming a triangle and the pelvis markers were used. Because the most proximal and distal (ie, upper and lower) instrumented vertebrae varied between patients, these marker subsets were customized per patient so that the triangular marker set was always located at the most proximal and distal fused segments possible for each patient. For example, if the posterior fusion extended from T5 to L2, the skin marker triangles T5L-T5R-T7 and T12-L1L-L1R were used for the analysis.

### Statistical analysis

A repeated measures analysis of variance was used to compare the effect of measurement (preoperatively and 3 and 12 months postoperatively) on the ROM of the segments. If a significant overall effect for “measurement” was found (within-subjects effect), post hoc Bonferroni tests were performed to identify significant differences between the measurements. The statistical analyses were performed using SPSS 23 for Mac OS X (IBM Corp., Armonk, NY, USA). *p*-Values less than .05 were considered statistically significant.

## Results

Fig. 2 shows the angles of the pelvis, PFP, and DFP in the sagittal, frontal, and transversal planes averaged across all

patients during a full gait cycle. Spinal fusion had only a minor effect on the kinematic curve pattern. The relative ROM of the PFP and DFP segments measured during gait analysis and the results of the repeated measures analysis of variance are presented in Table 4. After the spinal correction and fusion, PFP ROM in the transversal plane decreased by 29% at 3 months of follow-up ( $-2.4^\circ$ ,  $p=.006$ ). At 12 months of follow-up, the decrease was similar in magnitude (26%), but this decrease was no longer statistically significant ( $p=.109$ ).

No compensatory increase in the transversal ROM of DFP could be identified. Instead, the transversal DFP ROM decreased with a magnitude similar to that of PFP ROM of 32% at 3 months of follow-up, although this decrease did not reach statistical significance ( $p=.058$ ). At 12 months of follow-up, this decrease was similar in magnitude (32%) but now statistically significant ( $p=.019$ ).

In the sagittal plane, no changes were found in PFP ROM, whereas there was a significant decrease at 3 months of follow-up in DFP ROM ( $-36\%$ ,  $p=.013$ ). The latter was no longer significant at 12 months of follow-up ( $-28\%$ ,  $p=.152$ ).

In the frontal plane, neither the PFP nor the DFP showed a statistically significant change after surgery.

Finally, no statistically significant change in ROM was identified between the two postoperative measurements in any of the planes.

## Discussion

Despite its detrimental effect on spinal mobility, previous studies have shown only little to no effects of spinal fusion surgery on lower limb kinematics [4–6]. It was previously hypothesized that there are mechanisms at play during gait that compensate for this decreased spinal motion, but none were found in the pelvis or the lower limbs [4]. The present study aimed to identify possible compensatory mechanisms in the spine itself. It was hypothesized that, during gait, the unfused segment shows an increase in ROM to compensate for the loss of ROM of the fused segment. Gait analysis was performed preoperatively and 3 and 12 months postoperatively using a two-segment 3D spinal model.

To our knowledge, the present study is the first to use a two-segment 3D model of the spine to analyze spinal motion of patients with AIS during gait before and after posterior spinal correction and fusion. This approach provides unique information on the function of the spine during a dynamic everyday activity, such as walking. In comparison, previous studies on surgically treated patients with AIS analyzed the motion of individual spinal segments during static bending movements and did not use dynamic gait analysis [5,14–16]. Also, when dynamic gait analysis was performed, the spine was treated as a single segment [5,6,17]. The present study showed that the kinematic pattern of the analyzed segments was minimally affected by the spinal fusion (Fig. 2). The ROM of the PFP decreased, indicating that the mobility of the fused spine and the unfused spine in total is negatively affected



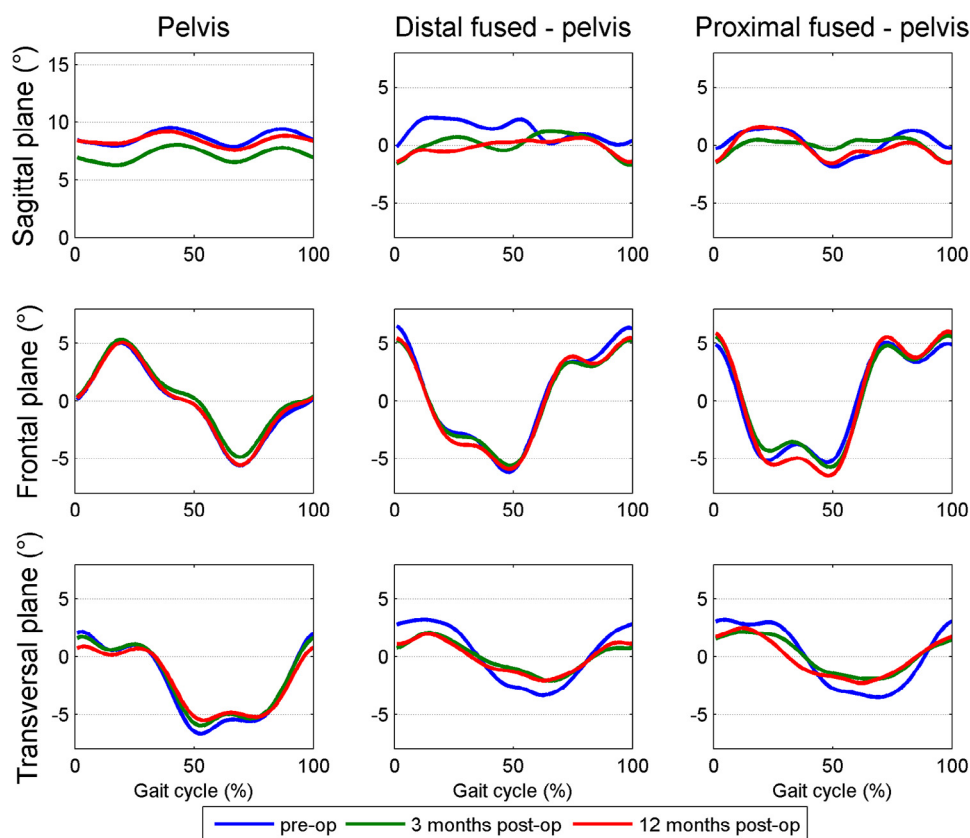


Fig. 2. Angles during the gait cycle. Distal fused: skin marker triad on the distal part of the spinal fusion. Proximal fused: skin marker triad on the proximal part of the spinal fusion. Both were expressed in the pelvis axis system, that is, DFP and PFP. DFP, distal part of the fusion in relation to the pelvis; PFP, proximal part of the fusion in relation to the pelvis.

(Table 4). The observed decreases were of a magnitude similar to that reported in previous studies that analyzed the spine as a single segment [5,6]. Surprisingly, the ROM of the DFP, representing the motion of the unfused spine, was also decreased. The magnitude of the decrease was similar to that of the proximal part relative to the pelvis. Accordingly, in contrast with our hypothesis, no evidence was found that the unfused part of the spine compensated for the decrease in ROM in the fused segments.

Other studies that used standing bending movements to analyze adjacent segment motion report contradictory results. Two studies reported an increase in unfused spinal-level motion [18,19], whereas others contradicted this finding [6,15,16,20,21]. Skalli et al. [16] even concluded that spinal motion reduction after fusion in static bending movements does not result in an increase of unfused segment motion, but instead is counterbalanced by an increased pelvic motion. Our data, however, did not support increased pelvic motion during gait after surgery (Fig. 1). In the present study, the motion patterns in the frontal and transversal planes of the PFP and DFP segments were highly similar before and after surgery. This finding possibly indicates a pre-existing limited spinal segment motion in the fused part because of the scoliosis. Unfortunately, no control group of healthy untreated subjects was included in the present study. However,

Syczewska et al. [22] have shown that in healthy subjects, in the frontal plane, the thoracic T7–T10 region is the most static spinal region during gait, whereas the more proximal C7–T7 and distal T10–S2 spinal levels bend to the support and swing leg, respectively. The relatively static T7–T10 region is a significant portion of the spinal levels fused during surgery. This finding gives an additional explanation for the lack of compensation in the unfused spine during gait, as, apparently, this part, even in healthy subjects, shows only little movement. Nevertheless, the surgery could still negatively affect adjacent segments potentially by small, immeasurable increases in spinal motion, direct surgical trauma, or altered sagittal alignment as increased degeneration of the unfused part of the spine after surgery has been observed [23]. Additionally, compensatory mechanisms might occur proximal to the fused spine, that is, in the proximal unfused thoracic spine or the shoulders.

Besides testing the hypothesis of a compensatory increase in motion in the unfused spine, the present study focused on postoperative recovery. Managing patient expectations on the level of recovery and return to preoperative physical activity is difficult as published data are scarce. Most clinicians allow return to non-contact sports after spinal fusion by 3 months, contact sports at 6 months, and collision sports by 12 months [24,25]. Actual return to unrestricted physical

Table 4  
Range of motion of segments during gait

	Overall ANOVA p-value	Measurement 1		Measurement 2		Measurement 3		1 versus 2		1 versus 3		2 versus 3				
		Mean (°)	SD	Mean (°)	SD	Mean (°)	SD	Change	95% CI	Change	95% CI	Change	95% CI			
DFP																
Sagittal	<b>.006</b>	8.0	0.8	5.1	0.7	5.8	0.6	-2.9 (-36%)	<b>.013</b>	0.622-5.132	-2.2 (-28%)	.152	-0.663 to 5.098	0.7 (13%)	.706	-2.498 to 1.179
Frontal	.226	13.5	1.7	11.3	1.0	12.1	1.7	-2.2 (-16%)	NA	-0.631 to 4.993	-1.4 (-10%)	NA	-2.541 to 5.381	0.8 (7%)	NA	-4.345 to 2.823
Transversal	<b>.010</b>	8.2	3.4	5.6	1.6	5.6	3.3	-2.6 (-32%)	.058	-0.086 to 5.303	-2.7 (-32%)	<b>.019</b>	0.442-4.913	-0.1 (-1%)	1.000	-2.554 to 2.692
PPF																
Sagittal	.287	5.5	2.7	4.3	1.3	4.9	1.8	-1.1 (-21%)	NA	-1.206 to 3.471	-0.6 (-11%)	NA	-1.066 to 2.287	0.5 (12%)	NA	-2.325 to 1.281
Frontal	.057	12.2	3.0	12.4	2.9	14.0	2.7	0.2 (2%)	NA	-1.542 to 1.161	1.8 (15%)	NA	-4.295 to 0.749	1.6 (13%)	NA	-3.929 to 0.763
Transversal	<b>.017</b>	8.3	2.9	5.9	2.2	6.2	3.0	-2.4 (-29%)	<b>.006</b>	0.728-4.102	-2.1 (-26%)	.109	-0.406 to 4.677	0.3 (5%)	.989	-3.024 to 2.466

CI, confidence interval; RM, repeated measures; ANOVA, analysis of variance; DFP, distal part of the fusion in relation to the pelvis; PFP, proximal part of the fusion in relation to the pelvis; SD, standard deviation.

An RM ANOVA was used to compare the effect of measurement on the ROM (Measurement 1: preoperatively, Measurement 2: 3 months postoperatively, and Measurement 3: 12 months postoperatively). If a significant overall effect for "measurement" was found (within-subjects effect), post hoc tests were performed to identify significant differences between the measurements. If the overall effect for measurement (overall RM ANOVA p-value) was not statistically significant, no post-hoc analysis was performed (NA). Bold values indicate statistical significance (p<.05).

activity occurs at approximately 52 weeks after surgery [26]. However, besides these survey-based studies, reports on actual measurements of spinal physical function are limited. Because of this paucity in the data, the second goal of the present study was to compare the results between 3 and 12 months after surgery. No statistically significant differences could be identified between the two postoperative measurements. Based on the present study, no further improvement should be expected with regard to spinal motion during gait between 3 and 12 months postoperatively. Whether the patients' subjective quality of spinal physical function improved was not investigated.

The present study's main limitation is the small sample size. The standard deviation was relatively large compared with the mean ROM, indicating a substantial intersubject variability as was also observed in earlier studies using spinal skin markers [7,8]. A small sample size also results in the potential risk of missing a relevant treatment effect. This would be the case if an effect in a small patient cohort was statistically non-significant but would result in a significant difference when a larger sample size was used (ie, a type II error). Effects that were not statistically significant, but were the 95% confidence interval (CI) covered an important effect must be interpreted as that the data are inconclusive about the effect of spinal fusion [27]. For example, the PFP segment decreased by 26% between Measurements 1 and 3 (p=.109, 95% CI [-0.406 to 4.677]; Table 4). For example, there was one close to a significant effect for PFP (fused plus unfused spine), which was an increase in PFP frontal ROM at 12 months after surgery. The effect was not significant (p=.057), but the 95% CI covered a potentially important effect: an increase in motion of the unfused plus fused segments (Table 3). Nevertheless, it is important to note that our main hypothesis was that there would be a compensatory increase in the ROM of the unfused spine (ie, DFP). All effects found for DFP, including the statistically non-significant ones, were in the opposite direction, thereby reinforcing our conclusion that no measurable increase in motion occurs in the unfused spine. Therefore, repeating these measurements with a larger sample size would probably neither show a compensatory increased motion of the unfused part of the spine.

Unfortunately, to the best of our knowledge, no literature is available regarding the minimal clinically important difference regarding the change in spinal motion after scoliosis treatment. This lack of literature is an excellent opportunity for future research, as functional outcome assessments, rather than static measurements like radiographs, could give vital information, in addition to patient-reported outcome measures and advance treatment quality [28].

Similar to previous reports, the present study used markers taped to the skin to measure spinal motion, which could cause errors in the measurements because of skin motion. Still, previous studies have already shown that skin markers allow for reliable and non-invasive measurement of spinal motion [7,22,29,30]. To limit the effect of intermeasurement

differences, a single experienced gait researcher applied the skin markers on all patients during each measurement. Still, a certain amount of error remains present. In future work, the use of markers, combined with x-ray assessment, may be considered to refine the location. Lastly, the patients demonstrated a variation in fused levels during the surgery. To cover this, the analysis was customized for each patient using a specific marker set that would always cover the fused and unfused segments. Unfortunately, although clinically relevant, the sample size was too small to analyze the effect of the level of fusion (ie, thoracic only vs. thoracic-lumbar).

## Conclusions

In summary, although the hypothesis of a compensatory increase in motion of the distal unfused spinal segments is a much researched and controversial topic [9,10], the present gait analysis actually shows a decrease rather than a compensatory increase in motion of the distal unfused spine. A previous study could neither identify compensatory mechanisms in the lower body [4]. Finally, it should be noted that we cannot exclude that compensatory mechanisms can be present proximal to the fused spine, that is, in the proximal unfused thoracic spine or the shoulders.

## References

- [1] Weinstein SL, Dolan L, Cheng JCY, Danielsson A, Morcuende J. Adolescent idiopathic scoliosis. *Lancet* 2008;371:1527–37.
- [2] de Kleuver M, Lewis SJ, Gernscheid NM, Kamper SJ, de Kleuver M, Lewis SJ, et al. Optimal surgical care for adolescent idiopathic scoliosis: an international consensus. *Eur Spine J* 2014;23:2603–18.
- [3] Tsutsui S, Pawelek J, Bastrom T, Lenke L, Lowe T, Betz R, et al. Dissecting the effects of spinal fusion and deformity magnitude on quality of life in patients with adolescent idiopathic scoliosis. *Spine* 2009;34:E653–8.
- [4] Holewijn RM, Kingma I, de Kleuver M, Schimmel JJP, Keijsers NLW. Spinal fusion limits upper body range of motion during gait without inducing compensatory mechanisms in adolescent idiopathic scoliosis patients. *Gait Posture* 2017;57:1–6.
- [5] Engsberg JR, Lenke LG, Uhrich ML, Ross SA, Bridwell KH. Prospective comparison of gait and trunk range of motion in adolescents with idiopathic thoracic scoliosis undergoing anterior or posterior spinal fusion. *Spine* 2003;28:1993–2000.
- [6] Lenke LG, Engsberg JR, Ross S, Reitenbach A, Blanke K, Bridwell KH. Prospective dynamic functional evaluation of gait and spinal balance following spinal fusion in adolescent idiopathic scoliosis. *Spine* 2001;26:E330–7.
- [7] Zhao GR, Ren LQL, Ren LQL, Hutchinson JR, Tian LM, Dai JS. Segmental kinematic coupling of the human spinal column during locomotion. *J Bionic Eng* 2008;5:328–34.
- [8] Needham R, Naemi R, Healy A, Chockalingam N. Multi-segment kinematic model to assess three-dimensional movement of the spine and back during gait. *Prosthet Orthot Int* 2016;40:624–35.
- [9] Zhang C, Berven SH, Fortin M, Weber MH. Adjacent segment degeneration versus disease after lumbar spine fusion for degenerative pathology: a systematic review with meta-analysis of the literature. *Clin Spine Surg* 2016;29:21–9.
- [10] Malakoutian M, Volkheimer D, Street J, Dvorak MFS, Wilke H-J, Oxland TR. Do in vivo kinematic studies provide insight into the degeneration of adjacent segments? A literature review. *Eur Spine J* 2015;24:1865–81.
- [11] Chockalingam N, Dangerfield PH, Giakas G, Cochrane T. Study of marker placements in the back for opto-electronic motion analysis. *Stud Health Technol Inform* 2002;88:105–9.
- [12] Crosbie J, Vachalathiti R, Smith R. Patterns of spinal motion during walking. *Gait Posture* 1997;5:6–12.
- [13] Wu G, Siegler S, Allard P, Kirtley C, Leardini A, Rosenbaum D, et al. ISB recommendation on definitions of joint coordinate system of various joints for the reporting of human joint motion—part I: ankle, hip, and spine. *J Biomech* 2002;35:543–8.
- [14] Samdani AF, Hwang SW, Miyajiri F, Lonner B, Marks MC, Sponseller PD, et al. Direct vertebral body derotation, thoracoplasty, or both: which is better with respect to inclinometer and Scoliosis Research Society-22 scores? *Spine* 2012;37:E849–53.
- [15] Hassani S, Graf A. Assessing spinal motion at different fusion levels in adolescents with idiopathic scoliosis. *Proc Gait Clin Mov Anal Soc* 2012;2012:163–4.
- [16] Skalli W, Zeller RD, Miladi L, Bourcureau G, Savidan M, Lavaste F, et al. Importance of pelvic compensation in posture and motion after posterior spinal fusion using CD instrumentation for idiopathic scoliosis. *Spine* 2006;31:E359–66.
- [17] Mahaudens P, Detrembleur C, Mousny M, Banse X. Gait in thoracolumbar/lumbar adolescent idiopathic scoliosis: effect of surgery on gait mechanisms. *Eur Spine J* 2010;19:1179–88.
- [18] Marks M, Bastrom T, Petcharaporn M, Shah S, Betz R, Samdani A, et al. The effect of time and fusion length on motion of the unfused lumbar segments in adolescent idiopathic scoliosis. *Spine Deform* 2015;3:549–53.
- [19] Marks M, Newton PO, Petcharaporn M, Bastrom TP, Shah S, Betz R, et al. Postoperative segmental motion of the unfused spine distal to the fusion in 100 patients with adolescent idiopathic scoliosis. *Spine* 2012;37:826–32.
- [20] Engsberg JR, Lenke LG, Reitenbach AK, Hollander KW, Bridwell KH, Blanke K. Prospective evaluation of trunk range of motion in adolescents with idiopathic scoliosis undergoing spinal fusion surgery. *Spine* 2002;27:1346–54.
- [21] Wilk B, Karol LA, Johnston CE, Colby S, Haideri N. The effect of scoliosis fusion on spinal motion: a comparison of fused and nonfused patients with idiopathic scoliosis. *Spine* 2006;31:309–14.
- [22] Syczewska MB, Öberg T, Karlsson D. Segmental movements of the spine during treadmill walking with normal speed. *Clin Biomech (Bristol, Avon)* 1999;14:384–8.
- [23] Akazawa T, Kotani T, Sakuma T, Minami S, Orita S, Inage K, et al. Modic changes and disc degeneration of non-fused segments 27 to 45 years after Harrington instrumentation for adolescent idiopathic scoliosis. *Spine* 2018;43:556–61.
- [24] Christman T, Li Y. Pediatric return to sports after spinal surgery. *Sport Heal* 2016;8:331–5.
- [25] Lehman RA, Kang DG, Lenke LG, Sucato DJ, Bevevino AJ, Spinal Deformity Study Group. Return to sports after surgery to correct adolescent idiopathic scoliosis: a survey of the Spinal Deformity Study Group. *Spine J* 2015;15:951–8.
- [26] Tarrant RC, O'Loughlin PF, Lynch S, Queally JM, Sheeran P, Moore DP, et al. Timing and predictors of return to short-term functional activity in adolescent idiopathic scoliosis after posterior spinal fusion: a prospective study. *Spine* 2014;39:1471–8.
- [27] Walters S. Consultants' forum: should post hoc sample size calculations be done? *Pharm Stat* 2009;8:163–9.
- [28] Furda AM, Bess AS, Meyer JN, Van Houten B. Gait behaviors as an objective surgical outcome in low back disorders: a systematic review. *Clin Biomech (Bristol, Avon)* 2015;30:111–32.
- [29] Konz RJ, Fatone S, Stine RL, Ganju A, Gard S, Ondra SL. A kinematic model to assess spinal motion during walking. *Spine* 2006;31:E898–906.
- [30] Needham R, Chockalingam N, Naemi R, Shannon T, Healy A. Validation of a multi-segment spinal model for kinematic analysis and a comparison of different data processing techniques. *Stud Health Technol Inform* 2012;176:151–4.