

VU Research Portal

Endovascular aortic aneurysm repair

Linsen, M.A.M.

2012

document version

Publisher's PDF, also known as Version of record

[Link to publication in VU Research Portal](#)

citation for published version (APA)

Linsen, M. A. M. (2012). *Endovascular aortic aneurysm repair: alternative strategies*.

General rights

Copyright and moral rights for the publications made accessible in the public portal are retained by the authors and/or other copyright owners and it is a condition of accessing publications that users recognise and abide by the legal requirements associated with these rights.

- Users may download and print one copy of any publication from the public portal for the purpose of private study or research.
- You may not further distribute the material or use it for any profit-making activity or commercial gain
- You may freely distribute the URL identifying the publication in the public portal ?

Take down policy

If you believe that this document breaches copyright please contact us providing details, and we will remove access to the work immediately and investigate your claim.

E-mail address:

vuresearchportal.ub@vu.nl



chapter 7

Pararenal aortic aneurysm repair using fenestrated endografts

Journal of Vascular Surgery 2012: in press

M.A.M. Linsen
V. Jongkind
D. Nio
A.W.J. Hoksbergen
W. Wisselink

ABSTRACT

Objective: We performed a systematic review of the current literature to analyze the immediate and follow-up results of fenestrated endovascular aortic aneurysm repair (F-EVAR) in patients with pararenal abdominal aortic aneurysms (AAAs).

Methods: The Medline, Embase, and Cochrane databases were searched to identify all studies reporting F-EVAR of pararenal AAAs published between January 2000 and May 2011. Two independent observers selected studies for inclusion, assessed the quality of the included studies, and performed the data extraction. Studies were selected based on specific predefined criteria. Outcomes were technical success (successfully completed procedure with endograft patency, preservation of target vessels, and no evidence of type I or III endoleak at postprocedural imaging), 30-day mortality, all-cause mortality, branch vessel patency, renal impairment, and secondary interventions. Between-study heterogeneity was calculated using I² statistics. Pooled estimates were calculated using a fixed-effects (I² <25%) or a random-effects (I² >25% to <50%) model.

Results: Nine studies were included reporting 629 patients who underwent F-EVAR for a pararenal AAA, of which 1622 target vessels were incorporated in an endograft design. Between-study heterogeneity was ≤ 41% for all outcomes. The pooled estimate (95% confidence interval [CI]) was 90.4% (87.7%-92.5%) for technical success, 2.1% (1.2%-3.7%) for 30-day mortality, and 16% (12.5%-20.4%) for all-cause mortality. Follow-up was 15 to 25 months. The pooled estimate (95% CI) during follow-up was 93.2% (90.4%-95.3%) for branch vessel patency, 22.2% (16%-30.1%) for renal impairment, and 17.8% (13.5-22.6%) for secondary interventions.

Conclusions: Promising immediate and midterm results (up to 2 years) support F-EVAR as a feasible, safe, and effective treatment in a relatively high-risk cohort of patients with pararenal AAAs.

Introduction

Abdominal aortic aneurysms (AAAs) that closely approach or involve the renal arteries can be classified as juxtarenal or thoracoabdominal (Crawford) type IV aneurysms.¹ Juxtarenal aneurysms extend proximally to the origin of the renal artery without involving the artery itself, whereas thoracoabdominal type IV include most or all of the entire abdominal aorta, including the renal arteries.¹ Compared with infrarenal AAAs, open surgical repair of these more complex aneurysms is characterized by more extensive mobilization of viscera to achieve adequate exposure of the abdominal aorta and may involve prolonged suprarenal aortic clamping and the need for revascularization of visceral vessels. Owing to inadequate proximal neck length, standard endovascular aortic aneurysm repair (EVAR) cannot provide a minimally invasive alternative for these complex aneurysms.

To overcome these problems, fenestrated EVAR (F-EVAR) has been developed. Fenestrated endografts are designed to extend the range of EVAR by moving the proximal sealing zone up to and above the level of the renal arteries, thereby providing endovascular repair of juxtarenal and Crawford type IV aneurysms. Following on the efforts of a few vascular specialists from Australia during the last decade, fenestrated endografts progressed from bench-top to broad clinical application and are now used commercially in Europe, Australia, and other locations.²⁻⁴

The present study performed a systematic review of the current literature to analyze the immediate and follow-up results of F-EVAR in patients with juxtarenal or Crawford type IV aortic aneurysms.

Methods

A systematic review was performed according to the guidelines of the Meta-analysis Of Observational Studies in Epidemiology group (MOOSE) and the Dutch Cochrane Centre.^{5,6} Two investigators (M.L. and V.J.) independently conducted a literature search, quality assessment, and data extraction.

Search strategy

A computer-assisted search was performed in the medical databases Medline, Embase, and the Cochrane Database of Systematic Reviews, from January 2000 to May 2011, using a combination of the following free-text words: *aortic aneurysm*, *AAA*, *complex aneurysm*, *juxtarenal*, *pararenal*, *suprarenal*, *endovascular repair*, *EVAR*, *graft*, *endograft*, *stent-graft*, *fenestrated*, and *F-EVAR*. With the assistance of a clinical librarian, an additional extensive search was performed using a combination of Medical Subject Heading (MeSH) terms: *vascular diseases*, *aortic aneurysm*; *aortic aneurysm, abdominal*; *vascular surgical procedures*, *vascular prosthesis*, *vascular grafting*, *endovascular procedures*, *endovascular technique*, *blood vessel prosthesis implantation*, and *stents*.

Electronic links to related articles and reference lists of selected articles were hand-searched to retrieve more studies. A hand-search for relevant journals and conference proceedings was not performed. Nor was a search for unpublished data or abstracts performed. Relevant studies were selected for full-text review based on title and abstract.

Study selection

Any prospective or retrospective study was considered. Studies were eligible if they (1) evaluated totally endovascular repair of juxtarenal or Crawford type IV aortic aneurysms using fenestrated endografts, (2) included at least 10 cases, (3) reported aneurysm morphology, (4) clearly stated the number of target vessels and their status (patent, stenosis, occlusion), (5) and observed a mean or median follow-up period of at least 6 months. Studies had to describe an original patient series. In case series reported on more than one occasion, the report containing the most complete outcomes information was included for analysis. The selection process excluded articles in languages other than English, Dutch, or German.

Methodological quality assessment

Each article included was assessed according to the critical review checklist of the Dutch Cochrane Centre⁵ (Table I). This list evaluates the quality of the study by using the following key statements that in the form of questions can be answered with yes (+), no (-), and uncertain (+/-).

The main points of this checklist are:

1. Clear definition of study population?
2. Can selection bias be excluded sufficiently?
3. Clear description of method of intervention?
4. Clear definition of outcomes and outcome assessment?
5. Independent assessment of outcome parameters?
6. Sufficient duration of follow-up?
7. No selective loss to follow-up?
8. Important confounders and prognostic factors identified?

Each study was further evaluated using a list of detailed study characteristics as proposed by the MOOSE group.⁶ Studies were scored on eight items. Each item was graded on a scale of 0 to 2, depending on the information available, so that the perfect study would have a maximum score of 16. Studies with a score of ≤ 8 were considered to be of poor methodological quality and were not included in our review. Quality score was determined by whether the study reported a consecutive series, a prospective series, reported excluded patients, indication for intervention, and a detailed description of target vessels, complications, and mortality.

Data extraction

Data were extracted using a standardized form. If recorded, the following information was extracted: publication year, country of origin, enrollment span, number of patients and their demographics (mean age, sex), anatomy (type of aneurysm, proximal neck length), procedure (type of endograft, procedure time, type of anesthesia used, contrast volume used, fluoroscopy time, number of target vessels, complications, results of postprocedural imaging), and follow-up results (mean/median follow-up, 30-day mortality, all-cause mortality, aneurysm rupture, hospital stay, renal impairment, new onset dialysis, branch vessel patency, reinterventions, major adverse events). Any discrepancies in judgment considering search strategy, selection of articles, quality assessment, or data extraction were resolved by discussion between all authors. Final decisions were made after consensus was reached.

Statistical analysis

Between-study statistical heterogeneity was assessed using I^2 statistics. In case of low heterogeneity ($I^2 < 25\%$) a fixed-effects model was used (Mantel-Haenszel

method), and in case of moderate heterogeneity ($I^2 < 50\%$), a random-effects model was used (DerSimonian-Laird model). Meta-analyses were performed for technical success, 30-day mortality, all-cause mortality, branch vessel patency, renal impairment, and secondary interventions. Pooled estimates are presented with 95% confidence intervals (CI). Analyses were done using Meta-Analyst, 3.0 beta software (Tufts Medical Center, Boston, Mass., USA).⁷

Definitions

The term *pararenal aortic aneurysm* was used to define juxtarenal and Crawford type IV aortic aneurysms. Technical success was defined as successfully completed F-EVAR procedure with endograft patency, preservation of target vessels, and no evidence of type I or III endoleak at postprocedural imaging. Renal impairment was defined as a transient or permanent increase in serum creatinine > 2 mg/dL or by a 30% increase compared with baseline levels. Renal impairment was also reported according to the Society for Vascular Surgery reporting standards as (1) no dialysis, (2) temporary dialysis, or (3) permanent dialysis, transplantation, or fatal outcome.⁸ Target vessel patency was defined as target vessels without (re)stenosis or occlusion that did not require a reintervention during follow-up. The reintervention rate was defined as a repeat procedure for complications that were aneurysm- or endograft-related (eg, endoleak, target vessel preservation related) or a result of the initial procedure (eg, wound infection).

Results

The search identified 173 articles, of which 44 studies were selected for full-text review based on title and abstract. Thirty-five studies were excluded after full-text review. Study flow and reasons for exclusion are presented in Fig. 1. We excluded two technical reports,^{9,10} three small case series or reports,^{3,11,12} six review articles,¹³⁻¹⁸ four articles that reported techniques other than fenestrated endografts,¹⁹⁻²² and four studies that reported data of an irrelevant cohort.²³⁻²⁶ One study was excluded because it only reported early outcome and no follow-up was described.²⁷ Several institutes were overrepresented in the selected studies. Only the largest, most complete series were used, leading to a reduction of 15 articles.^{2,28-41}

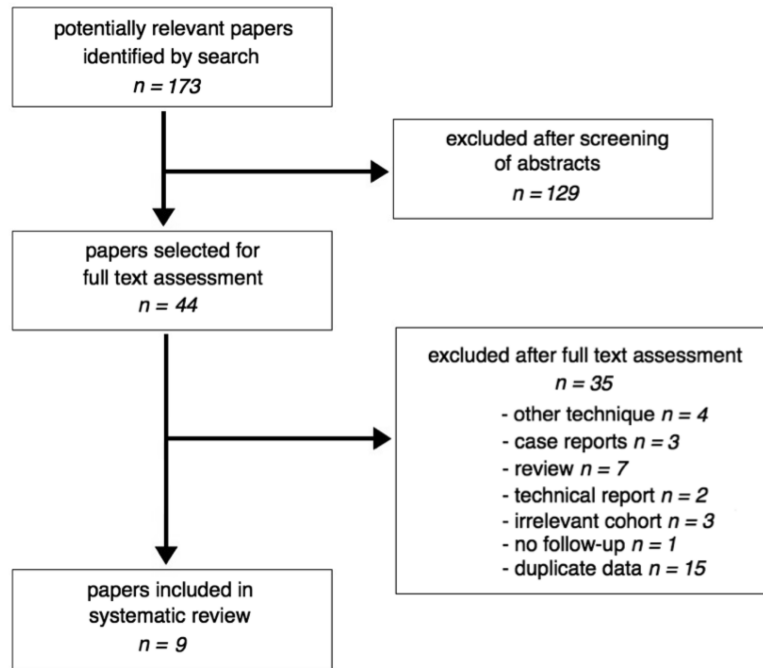


Figure 1: Flow chart illustrates study selection.

Study quality

Nine studies were included in this analysis.⁴²⁻⁵⁰ All studies were observational, two were of prospective and seven of retrospective design. Quality assessment of the studies (Table 1) showed a suspected selection bias of patients in most studies. The total quality score of the description of the study characteristics is shown in the last column of Table 1. Although operative and follow-up data were well documented, their quality was influenced on whether data were retrospectively or prospectively acquired and if patients were consecutively included.

Table 1: Quality assessment list of included studies.

	Clear definition of study population?	Can selection bias be excluded sufficiently?	Clear description of method of intervention?	Clear definition of outcomes and outcome assessment?	Independent assessment of outcome parameters?	Sufficient duration of follow-up?	None selective loss to follow-up?	Important confounders and prognostic factors identified?	Quality score of description of study characteristics?
Semmens	-	-	+	+/-	-	+	+	+	10
O'Neill	+	-	+	+	-	+	+	+	11
Scurr	+	-	+	+	-	+	+	+	12
Ziegler	+	-	+	+	-	+	+	+	10
Kristmundson	+	+/-	+	+	-	+	+	+	13
Greenberg	+	+	+	+	+/-	+	+	+	16
Verhoeven	+	-	+	+	-	+	+	+	10
Amiot	+	-	+	+	-	+	+	+	10
Tambyraja	+	-	+	+/-	-	+	+	+	13

Preprocedural patient characteristics

The included articles represented 629 patients undergoing F-EVAR of pararenal AAAs between 1997 and 2010. Age was reported using mean and median (range, 70.5-75.5 years), and 557 patients (88.6%) were men. Aneurysm size was reported by eight studies, and both mean and median were used (range, 55.1-68 mm). Only four studies reported mean or median proximal neck length (range, 3.6-9.2 mm). Most patients had significant comorbidities, were deemed high risk for open repair, and were not eligible for conventional EVAR. Only four studies reported the American Society of Anesthesiologists (ASA) score. Previous open surgical AAA repair had been performed in 31 patients (4.9%), and 12 (1.9%) had undergone

previous EVAR. Mean or median duration of follow-up was 15 to 25 months. Patient and study characteristics are summarized in Table 2.

The included studies all used Zenith fenestrated endografts (Cook Inc, Indianapolis, Ind., USA). This device is a modular system that contains a tubular proximal fenestrated component, a distal bifurcated component, and one limb extension. Endografts are individually customized according to the precise plans of the location of the visceral arteries (target vessels) to be preserved. Most target vessels are stented open using bare or covered balloon-expandable stents. This ensures proper alignment of the fenestration and the orifice of the target vessel. A step-by-step technical description was published by Moore et al.⁵¹

Table 2: Demographics and patient characteristics of included studies.

	Country	Enrollment span	No. of patients	Age (years)	Gender M/F	Aneurysm size (mm)	Proximal neck length (mm)	Follow-up (months)
Semmens	Australia	1997-2004	58	75.5	51/7	NR	NR	18
O'Neill	USA	2001-2005	119	75	98/21	65	8	19
Scurr	UK	2003-2006	45	73 *	41/4	68 *	6 *	24 *
Ziegler	Germany	1999-2006	60	70.5	54/6	55.1	NR	23
Kristmundson	Sweden	2002-2007	54	72 *	46/8	60 *	NR	25 *
Greenberg	USA	2005-2006	30	75	24/6	61.4	9.2	#
Verhoeven	NL	2001-2009	100	72.6	87/13	60 *	3.6	24 *
Amiot	France	2004-2009	134	73 *	129/5	56 *	NR	15 *
Tambyraja	UK	2005-2010	29	74 *	27/2	68	NR	20 *

*results expressed as median, NR = not reported, # reported follow-up: n=27 of 30 at 1 year and n=23 of 30 at 2 years

Procedural data and early outcome

A total of 1622 target vessels were incorporated in an endograft design, and the renal artery was included 1144 times (Table 3). Each patient received between two and three fenestrations (Table 3). Details of whether fenestrations were stented open or not, and the number of bare and/or covered stents used, were poorly described. Only four studies provided the type of anesthesia used, indicating general anesthesia was used in 61.6%, and local or regional was used in the rest.

Table 3: Total of incorporated target vessel and their distribution among visceral vessels.

	Target vessels	Renal arteries	SMA	Celiac axis
Semmens	116	91	24	1
O'Neill	302	225	76	1
Scurr	117	80	35	2
Ziegler	119	88	22	9
Kristmundson	134	94	37	3
Greenberg	77	57	20	0
Verhoeven	275	192	78	5
Amiot	403	265	NR	NR
Tambyraja	79	52	25	2

NR, Not reported; SMA, superior mesenteric artery.

Procedure time was reported using both mean and median and was between 180 and 350 minutes. The mean or median reported fluoroscopy time was 34.3 to 78 minutes, and 96.3 to 270 mL of contrast volume was used. All studies provided data to determine technical success. The pooled estimate for technical success was 90.4% (95% CI, 87.7-92.5%; $I^2 = 20\%$; Fig. 2). Two patients required immediate open conversion. In one patient, an occlusion of the native aortic bifurcation was identified after successful endograft implantation, and an aortobifemoral bypass graft was placed. The other patient required conversion during endograft placement. Owing to twisting of the ipsilateral limb, the top cap

could not be retrieved and further attempts resulted in crushing the already-placed renal stents. In four patients, fenestrated endograft placement had to be abandoned. In two patients, correct alignment of fenestration with target vessel ostia could not be achieved. The third patient was found to have an incorrect endograft size, and in the fourth patient, the imaging equipment failed intraoperatively. Both patients were rescheduled for FEVAR at a later time.

At postprocedural imaging, the incidence of type I and III endoleaks was 4.6%, and preservation of target vessels was successful in 1603 vessels (99%). Causes for target vessel loss included planning errors, incorrect endograft deployment, failed target vessel catheterization, and target vessel dissection.

No intraoperative deaths were reported. Ten patients died \leq 30 days after the primary procedure. The pooled estimate for 30-day mortality was 2.1% (95% CI, 1.2%-3.7%; $I^2 = 0\%$; Fig 3). Causes of death were myocardial infarction in three, mesenteric ischemia in two, pulmonary complications in two, and multi-organ failure in three (two after a major bleeding and one after conversion).

Follow-up results

Target vessel patency was reported in all studies. The pooled estimate for target vessel patency at the end of follow-up was 93.2% (95% CI, 90.4%-95.3%; $I^2 = 41\%$; Fig. 4). The pooled estimate for renal impairment at the end of follow-up, as reported by six studies, was 22.2% (95% CI, 16%-30.1%; $I^2 = 39\%$). Only 13 patients (2.1%) required dialysis, but whether dialysis was transient or permanent was poorly described. No patient required renal transplantation, and no fatal outcomes after renal impairment were described.

The pooled estimate for all-cause mortality at the end of follow-up was 16% (95% CI, 12.5%-20.4%; $I^2 = 29\%$). Six deaths related to the aneurysm or the procedure occurred during follow-up at $>$ 30 days postoperatively. One patient died after aneurysm rupture at 10 months, probably caused by a type I endoleak. One patient died on day 45 as a result of mesenteric ischemia. Two patients died of complications subsequent to renal angioplasty in one and surgery of the groin related to infection in the other). One patient died of multi-organ failure related to massive atheroembolism, and one died in connection with an aortoduodenal fistula at 72 months. Nonfatal and nonrenal morbidity was poorly described or not mentioned at all, hindering an accurate analysis of the reported data.

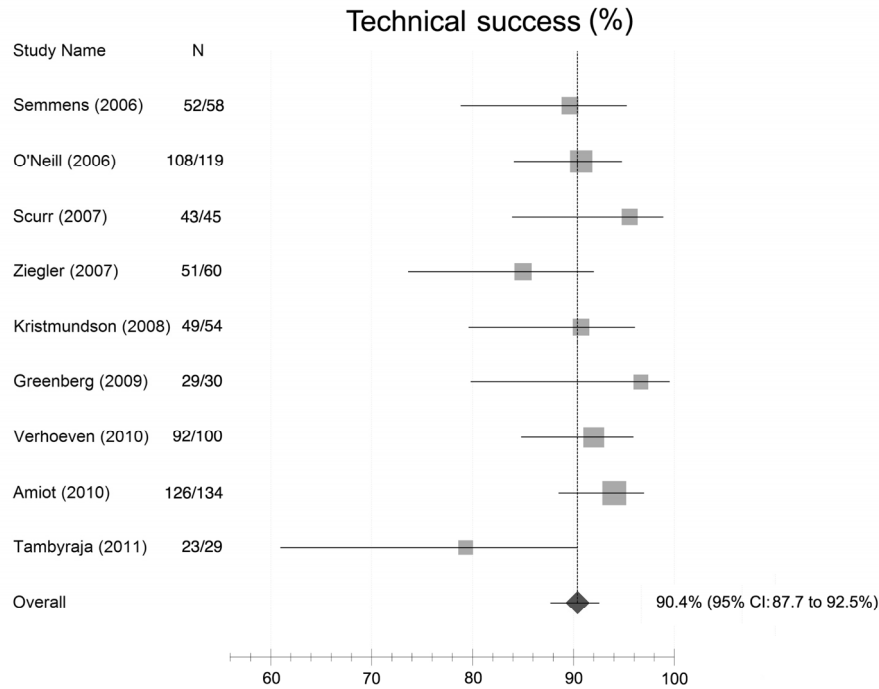


Figure 2: Forest plot shows technical success rate in all studies, defined as successfully completed fenestrated endovascular aneurysm repair procedure with endograft patency, preservation of target vessels, and no evidence of type I or III endoleak at postprocedural imaging. *CI*, Confidence interval.

All authors reported patients that required reinterventions. At the end of follow-up, the pooled estimate for reinterventions was 17.8% (95% CI, 13.5%-22.6%; I² = 34%). This included one secondary conversion to open repair after aneurysm growth caused by a type I endoleak and six patients requiring laparotomy for various reasons (three for suspected mesenteric ischemia, two for acute bleeding, and one for open repositioning of the endograft and a bypass from the right iliac artery to the right renal artery). Other secondary procedures were evacuation of a retroperitoneal hematoma in two patients, endoleak repair in 40 (16 type I, 14 type II, and 10 type III), target vessel patency related in 36, wound and access-site related in 12, and placement of an iliac limb extension in six.

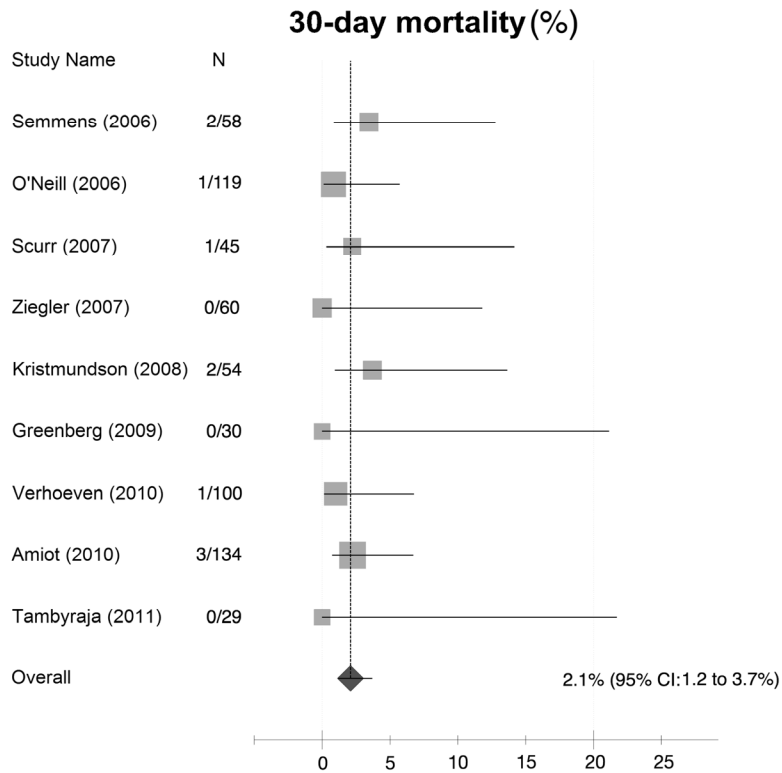


Figure 3: Forest plot shows 30-day mortality for all studies. *CI*, Confidence interval.

Discussion

The primary aim of F-EVAR is successful aneurysm exclusion in a surviving patient who is protected from rupture with target vessel patency and is free of major adverse events. The results of our systematic review indicate that F-EVAR of pararenal aneurysms can be performed with a low 30-day mortality rate of 2.1%. This is comparable to the 1.7% rate reported after conventional EVAR and appears to be superior to the 2.9% rate after open pararenal AAA repair, as reported in a recent meta-analysis.^{52,53} This is remarkable considering that most of the patients in our analysis had significant comorbidities and were deemed “unfit” or “high risk” for open repair. Moreover, a number of patients underwent F-EVAR after previous open aortic surgery or conventional EVAR. In comparison, the reported 30-day mortality by the EVAR 2 trial (patients considered high risk and unfit for open repair

that underwent conventional EVAR) was more than three times higher (6.8%).⁵⁴ Although remarkable, the difference is probably caused by a more moderate inclusion of patients by studies included in this meta-analysis. This hypothesis is supported by the relatively low all-cause mortality of 16% found in this meta-analysis.

The technique of F-EVAR is more complex than that of conventional EVAR. It requires appropriate patient selection, high-resolution preoperative imaging, accurate procedural planning, proper device design, and excellent endovascular and catheter skills. Failure to accomplish this may result in target vessel loss, endoleaks, or the need for conversion to open repair. Technical success was achieved in 90.4% of all cases. The immediate conversion rate was low (0.3%) and comparable to conventional EVAR (0.8%).⁵²

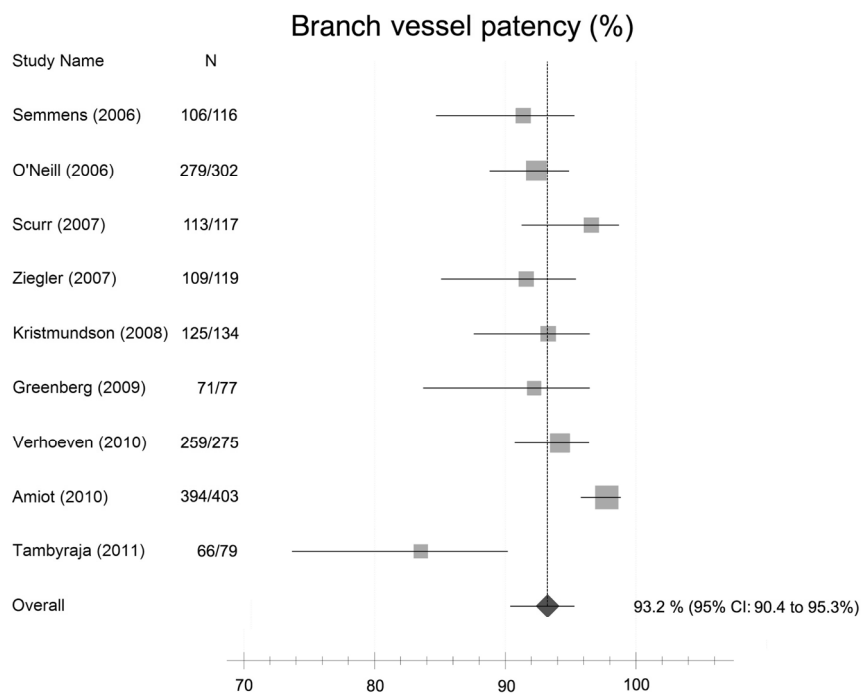


Figure 4: Forest plot shows branch vessel patency for all studies. *CI*, Confidence interval.

Owing to the definition used, technical success was highly dependent on whether intraoperative complications were addressed during the initial procedure or at a later stage. Technical success was determined at the end of the procedure, and therefore, the interventions that were done within the first postoperative days were considered a failure in technical success. This resulted in higher secondary intervention and lower technical success rates. Furthermore, failure in technical success is not always a failure in treatment success. For example, primary type I endoleaks represent a failure to exclude an aneurysm and are a cause of aneurysm growth with the risk of aneurysm rupture. However, small endoleaks found on postprocedural angiography may resolve in time without consequences or the need for reintervention.⁴³⁻⁴⁵ Moreover, target vessel loss without clinical sequelae has been reported.⁴⁴⁻⁴⁶

The durability of F-EVAR has been questioned. There is a concern with target vessel patency and renal impairment.³¹ Loss of branch vessel patency can occur during the initial procedure or over time due to endograft migration, component separation, stent fracture, or in-stent stenosis. Very few target vessels were lost during the initial procedure, and branch vessel patency during follow-up was 93.2%. The combined transient and permanent renal impairment rate in this analysis was 22.2%. This seems comparable to that reported for open pararenal aneurysm repair,⁵³ but accurate comparison is difficult due to the wide variety of definitions used. The incidence of new-onset dialysis, however, was 2.1% in this review compared with 3.3% reported after open pararenal repair.⁵³ Renal dysfunction was obviously related to the loss of renal artery patency but also occurred in patients with confirmed patency. Early renal impairment is likely associated with atheroembolic events that occur due to device and catheter manipulation. The use of nephrotoxic contrast agents can also alter renal function, especially when preoperative renal function is already impaired.

EVAR is associated with higher rates of reintervention than open repair.⁵⁵ The reintervention rate of F-EVAR in this analysis was 17.8%. Taking into account a shorter follow-up (up to 2 years), but also the more complex endograft design, this result seems comparable with the 20% reintervention rate after reported at the 4-year follow-up after conventional EVAR.⁵⁵ Noteworthy is the relatively high number of type III endoleaks. Compared with standard EVAR, F-EVAR requires an additional proximal fenestrated component. The additional connection between this component and the bifurcated component may result in a higher type III endoleak

rate. This complication can be easily eliminated by increasing the overlapping zone between the two main body components.^{45,47}

This systematic review shows that since the introduction of F-EVAR, only a small number of dedicated centers have accumulated significant experience with this technique, and information about outcomes, particularly in the longer term, remains limited. The 629 patients in the pooled data represent just a part of the total number of patients treated with this technique worldwide. Other data have not (yet) been published or have been published combined with results for thoracoabdominal aneurysm repair. The included studies well described aneurysm type and patient characteristics; however, only four studies stated proximal aortic neck length and a wide variety of definitions to describe the extent of aneurysmal disease were used. It is therefore not clear if treatment of the same aneurysm morphology was compared. The incorporation of more target vessels in endograft design to treat more complex aneurysms clearly results in an increased complication rate and higher risk for patency loss.

Furthermore, most of the patients were deemed at high risk for open repair, but only four studies reported ASA scores. How many patients were actually at high risk for open surgery is unclear. Owing to these confounders, some clinical heterogeneity was suspected between studies; nevertheless, we decided to perform a pooled analysis for the different outcomes. Between-study statistical heterogeneity subsequently was low or at least moderate, with an I^2 value of < 41% for all outcomes.

The included studies represent a relatively long period for a new technique under development. This period includes the early years when fenestrated endografts were in their infancy. We have to take in consideration that every new procedure, especially one that is technically challenging, is subject to a learning curve. Furthermore, improvements in techniques and materials have been made over time. These factors will likely have negatively influenced the early outcomes. However, less demanding cases were selected during the early years, and single scallops or fenestrations were incorporated in the endograft design. More challenging anatomies were targeted at a later stage, incorporating three fenestrations, one for each renal artery and one for the superior mesenteric artery and a scallop for the celiac axis.

Conclusion

This review shows that the immediate and midterm results (up to 2 years) for F-EVAR are very promising. Pooled results support F-EVAR as a feasible, safe, and effective treatment in patients with pararenal AAAs and significant comorbidities. F-EVAR can be performed with good technical success and with acceptable 30-day mortality and target vessel patency. However, postoperative deterioration of renal function is a common complication, technical complications can occur intraoperatively and postoperatively, and as in conventional EVAR, a significant amount of reintervention is necessary. Obviously, the long-term durability remains to be investigated, and due to missing randomized trials, comparison with open pararenal AAA repair is difficult. For now, F-EVAR, in the hands of an experienced surgeon, can be a viable alternative to open pararenal AAA repair. It may be the only option for patients with pararenal AAAs who are considered high risk for open aneurysm repair and who otherwise would be denied treatment.

References

1. Fillinger MF, Greenberg RK, McKinsey JF, Chaikof EL, Society for Vascular Surgery Ad Hoc Committee on TEVAR Reporting Standards. Reporting standards for thoracic endovascular aortic repair (TEVAR). *J Vasc Surg* 2010;52:1022-33.
2. Anderson JL, Berce M, Hartley DE. Endoluminal aortic grafting with renal and superior mesenteric artery incorporation by graft fenestration. *J Endovasc Ther* 2001;8:3-15.
3. Stanley BM, Semmens JB, Lawrence-Brown MM, Goodman MA, Hartley DE. Fenestration in endovascular grafts for aortic aneurysm repair: new horizons for preserving blood flow in branch vessels. *J Endovasc Ther* 2001;8:16-24.
4. Browne TF, Hartley D, Purchas S, Rosenberg M, Van Schie G, Lawrence-Brown M. A fenestrated covered suprarenal aortic stent. *Eur J Vasc Endovasc Surg* 1999;18:445-9.
5. Cochrane Collaboration. Checklist III for evaluation of observational studies. Available at: <http://dcc.cochrane.org/sites/dcc.cochrane.org/files/uploads/cohort.pdf>.
6. Stroup DF, Berlin JA, Morton SC, Olkin I, Williamson GD, Rennie D, et al. Meta-analysis of observational studies in epidemiology: a proposal for reporting: meta-analysis of Observational Studies in Epidemiology (MOOSE) group. *JAMA* 2000;283:2008-12.

7. Wallace BC, Schmid CH, Lau J, Trikalinos TA. Meta-Analyst: software for meta-analysis of binary, continuous and diagnostic data. *BMC Med Res Methodol* 2009;9:80.
8. Chaikof EL, Blankensteijn JD, Harris PL, White GH, Zarins CK, Bernhard VM, et al. Reporting standards for endovascular aortic aneurysm repair. *J Vasc Surg* 2002;35:1048-60.
9. Ohrlander T, Sonesson B, Ivancev K, Resch T, Dias N, Malina M. The chimney graft: a technique for preserving or rescuing aortic branch vessels in stent-graft sealing zones. *J Endovasc Ther* 2008;15:427-32.
10. Soltesz EG, Greenberg RK. Endovascular repair of thoracoabdominal aortic aneurysms with fenestrated-branched stent-grafts. *Operat Tech Thorac Cardiovasc Surg*; 2010;5:86-99.
11. Tse LW, Steinmetz OK, Abraham CZ, Valenti DA, Mackenzie KS, Obrand DI, et al. Branched endovascular stent-graft for suprarenal aortic aneurysm: the future of aortic stent-grafting? *Can J Surg* 2004;47:257-62.
12. Bohm G, Berenberg J, Gschwendtner M. Endovascular therapy of a complex infrarenal aorta aneurysm by means of 4-fold fenestrated prosthesis - 6-month follow up. *Z Z Gefässmedizin* 2010;7:12-5.
13. Haulon S, O'Brien N. Advances in endovascular repair for complex aneurysms. *Br J Surg* 2011;98:163-5.
14. Chuter TA. Fenestrated and branched stent-grafts for thoracoabdominal, pararenal and juxtarenal aortic aneurysm repair. *Semin Vasc Surg* 2007;20:90-6.
15. Ricco JB. Fenestrated stent grafting for aortic aneurysm in Europe. *Eur J Vasc Endovasc Surg* 2010;39:545-6.
16. Mastracci TM. Fenestrated endografts for complex abdominal aortic aneurysms. *Perspect Vasc Surg Endovasc Ther* 2010;22:214-8.
17. Oderich GS, Ricotta JJ, 2nd. Modified fenestrated stent grafts: device design, modifications, implantation, and current applications. *Perspect Vasc Surg Endovasc Ther* 2009;21:157-67.
18. Chuter TA. Branched stent-grafts for endovascular repair of aortic and iliac aneurysms. *Tech Vasc Interv Radiol* 2005;8:56-60.
19. Hiramoto JS, Chang CK, Reilly LM, Schneider DB, Rapp JH, Chuter TA. Outcome of renal stenting for renal artery coverage during endovascular aortic aneurysm repair. *J Vasc Surg* 2009;49:1100-6.
20. Donas KP, Torsello G, Austermann M, Schwindt A, Troisi N, Pitoulias GA. Use of abdominal chimney grafts is feasible and safe: short-term results. *J Endovasc Ther* 2010;17:589-93.
21. Bruen KJ, Fezor RJ, Daniels MJ, Beck AW, Lee WA. Endovascular chimney technique versus open repair of juxtarenal and suprarenal aneurysms. *J Vasc Surg* 2011;53:895-904.
22. Coscas R, Kobeiter H, Desgranges P, Becquemin JP. Technical aspects, current indications, and results of chimney grafts for juxtarenal aortic aneurysms. *J Vasc Surg* 2011;53:1520-7.

23. Sobocinski J, Azzaoui R, D'Elia P, Koussa M, Decoene C, Haulon S. Endovascular exclusion of thoracoabdominal aneurysms: indications and results. *IRBM* 2009;30:S58-62.
24. Troisi N, Donas KP, Austermann M, Tessarek J, Umscheid T, Torsello G. Secondary procedures after aortic aneurysm repair with fenestrated and branched endografts. *J Endovasc Ther* 2011;18:146-53.
25. Austermann M, Donas KP, Panuccio G, Troisi N, Torsello G. Pararenal and thoracoabdominal aortic aneurysm repair with fenestrated and branched endografts: lessons learned and future directions. *J Endovasc Ther* 2011;18:157-60.
26. Kienz P, Austermann M, Tessarek J, Torsello G. Treatment of complex aortic aneurysms with fenestrated endografts-first results. *Zentralbl Chir* 2010;135:427-32.
27. Manning BJ, Agu O, Richards T, Ivancev K, Harris PL. Early outcome following endovascular repair of pararenal aortic aneurysms: triple versus double- or single-fenestrated stent-grafts. *J Endovasc Ther* 2011;18:98-105.
28. Greenberg R, Eagleton M, Mastracci T. Branched endografts for thoracoabdominal aneurysms. *J Thorac Cardiovasc Surg* 2010;140:S171-8.
29. Dowdall JF, Greenberg RK, West K, Moon M, Lu Q, Francis C, et al. Separation of components in fenestrated and branched endovascular grafting: branch protection or a potentially new mode of failure? *Eur J Vasc Endovasc Surg* 2008;36:2-9.
30. Greenberg RK, Haulon S, Lyden SP, Srivastava SD, Turc A, Eagleton MJ, et al. Endovascular management of juxtarenal aneurysms with fenestrated endovascular grafting. *J Vasc Surg* 2004;39:279-87.
31. Haddad F, Greenberg RK, Walker E, Nally J, O'Neill S, Kolin G, et al. Fenestrated endovascular grafting: the renal side of the story. *J Vasc Surg* 2005;41:181-90.
32. Greenberg RK, Haulon S, O'Neill S, Lyden S, Ouriel K. Primary endovascular repair of juxtarenal aneurysms with fenestrated endovascular grafting. *Eur J Vasc Endovasc Surg* 2004;27:484-91.
33. Greenberg RK, West K, Pfaff K, Foster J, Skender D, Haulon S, et al. Beyond the aortic bifurcation: branched endovascular grafts for thoracoabdominal and aortoiliac aneurysms. *J Vasc Surg* 2006;43:879-86.
34. Beck AW, Bos WT, Vourliotakis G, Zeebregts CJ, Tielliu IF, Verhoeven EL. Fenestrated and branched endograft repair of juxtarenal aneurysms after previous open aortic reconstruction. *J Vasc Surg* 2009;49:1387-94.
35. Vourliotakis G, Bos WT, Beck AW, Van Den Dungen JJ, Prins TR, Verhoeven EL. Fenestrated stent-grafting after previous endovascular abdominal aortic aneurysm repair. *J Cardiovasc Surg (Torino)* 2010;51:383-9.
36. Muhs BE, Verhoeven EL, Zeebregts CJ, Tielliu IF, Prins TR, Verhagen HJ, et al. Mid-term results of endovascular aneurysm repair with branched and fenestrated endografts. *J Vasc Surg* 2006;44:9-15.

37. Verhoeven EL, Prins TR, Tielliu IF, van den Dungen JJ, Zeebregts CJ, Hulsebos RG, et al. Treatment of short-necked infrarenal aortic aneurysms with fenestrated stent-grafts: short-term results. *Eur J Vasc Endovasc Surg* 2004;27:477-83.
38. Verhoeven EL, Tielliu IF, Muhs BE, Bos WT, Zeebregts CJ, Prins TR, et al. Fenestrated and branched stent-grafting: a 5-years experience. *Acta Chir Belg* 2006;106:317-22.
39. Verhoeven EL, Muhs BE, Zeebregts CJ, Tielliu IF, Prins TR, Bos WT, et al. Fenestrated and branched stent-grafting after previous surgery provides a good alternative to open redo surgery. *Eur J Vasc Endovasc Surg* 2007;33:84-90.
40. Halak M, Goodman MA, Baker SR. The fate of target visceral vessels after fenestrated endovascular aortic repair general considerations and mid-term results. *Eur J Vasc Endovasc Surg* 2006;32:124-8.
41. Haulon S, Amiot S, Magnan PE, Becquemin JP, Lermusiaux P, Koussa M, et al. An analysis of the French multicentre experience of fenestrated aortic endografts: medium-term outcomes. *Ann Surg* 2010;251:357-62.
42. Semmens JB, Lawrence-Brown MM, Hartley DE, Allen YB, Green R, Nadkarni S. Outcomes of fenestrated endografts in the treatment of abdominal aortic aneurysm in western Australia (1997-2004). *J Endovasc Ther* 2006;13:320-9.
43. O'Neill S, Greenberg RK, Haddad F, Resch T, Sereika J, Katz E. A prospective analysis of fenestrated endovascular grafting: intermediate term outcomes. *Eur J Vasc Endovasc Surg* 2006;32:115-23.
44. Scurr JR, Brennan JA, Gilling-Smith GL, Harris PL, Vallabhaneni SR, McWilliams RG. Fenestrated endovascular repair for juxtarenal aortic aneurysm. *Br J Surg* 2008;95:326-32.
45. Ziegler P, Avgerinos ED, Umscheid T, Perdikides T, Stelter WJ. Fenestrated endografting for aortic aneurysm repair: a 7-year experience. *J Endovasc Ther* 2007;14:609-18.
46. Kristmundsson T, Sonesson B, Malina M, Björnses K, Dias N, Resch T. Fenestrated endovascular repair for juxtarenal aortic pathology. *J Vasc Surg* 2009;49:568-74.
47. Greenberg RK, Sternbergh WC 3rd, Makaroun M, Ohki T, Chuter T, Bharadwaj P, et al. Fenestrated Investigators. Intermediate results of a United States multicenter trial of fenestrated endograft repair for juxtarenal abdominal aortic aneurysms. *J Vasc Surg* 2009;50:730-737e1.
48. Verhoeven EL, Vourliotakis G, Bos WT, Tielliu IF, Zeebregts CJ, Prins TR, et al. Fenestrated stent grafting for short-necked and juxtarenal abdominal aortic aneurysm: an 8-year single-centre experience. *Eur J Vasc Endovasc Surg* 2010;39:529-36.
49. Amiot S, Haulon S, Becquemin JP, Magnan PE, Lermusiaux P, Goueffic Y, et al. Fenestrated endovascular grafting: the French multicentre experience. *Eur J Vasc Endovasc Surg* 2010;39:537-44.

50. Tambyraja AL, Fishwick NG, Bown MJ, Nasim A, McCarthy MJ, Sayers RD. Fenestrated aortic endografts for juxtarenal aortic aneurysm: medium term outcomes. *Eur J Vasc Endovasc Surg* 2011;42:54-8.
51. Moore R, Hinojosa CA, O'Neill S, Mastracci TM, Cinà CS. Fenestrated endovascular grafts for juxtarenal aortic aneurysms: a step by step technical approach. *Catheter Cardiovasc Interv* 2007;69:554-71.
52. Greenhalgh RM, Brown LC, Kwong GP, Powell JT, Thompson SG, EVAR trial participants. Comparison of endovascular aneurysm repair with open repair in patients with abdominal aortic aneurysm (EVAR trial 1), 30-day operative mortality results: randomised controlled trial. *Lancet* 2004;364:843-8.
53. Jongkind V, Yeung KK, Akkersdijk GJ, Heidsieck D, Reitsma JB, Tangelder GJ, et al. Juxtarenal aortic aneurysm repair. *J Vasc Surg* 2010;52:760-7.
54. EVAR trial participants. Endovascular aneurysm repair and outcome in patients unfit for open repair of abdominal aortic aneurysm (EVAR trial 2): randomised controlled trial. *Lancet* 2005;365:2187-92.
55. EVAR trial participants. Endovascular aneurysm repair versus open repair in patients with abdominal aortic aneurysm (EVAR trial 1): randomised controlled trial. *Lancet* 2005;365:2179-86.