

# VU Research Portal

## The eye as a window to the brain

Balk, L.J.

2014

### **document version**

Publisher's PDF, also known as Version of record

[Link to publication in VU Research Portal](#)

### **citation for published version (APA)**

Balk, L. J. (2014). *The eye as a window to the brain: Optical coherence tomography in MS.* [, Vrije Universiteit Amsterdam].

### **General rights**

Copyright and moral rights for the publications made accessible in the public portal are retained by the authors and/or other copyright owners and it is a condition of accessing publications that users recognise and abide by the legal requirements associated with these rights.

- Users may download and print one copy of any publication from the public portal for the purpose of private study or research.
- You may not further distribute the material or use it for any profit-making activity or commercial gain
- You may freely distribute the URL identifying the publication in the public portal

### **Take down policy**

If you believe that this document breaches copyright please contact us providing details, and we will remove access to the work immediately and investigate your claim.

### **E-mail address:**

[vuresearchportal.ub@vu.nl](mailto:vuresearchportal.ub@vu.nl)

# Chapter 5

## Summarising discussion and conclusions

Parts of the introduction have also been published in a recent review on OCT in MS.

LJ Balk, A Petzold

A. Current and future potential of retinal OCT in Multiple Sclerosis  
with and without optic neuritis

*Neurodegener Dis Manag.* 2014;4:165-76



This thesis aimed to provide more insight in the mechanisms of neuroaxonal degeneration in longstanding MS by using OCT and to determine the added value of OCT in management of the disease. This final chapter summarises and critically discusses the results of the methodological and clinical data. Finally, we address the overall conclusions and the possible implications for future research.

## METHODOLOGICAL CONSIDERATIONS

### Physiological variation

During the past decade, OCT has been described as a promising method for imaging of neuroaxonal degeneration in MS.<sup>1,2</sup> Because OCT was suggested to be especially useful in longitudinal studies, the reliability of the technique is very important. This is even further underpinned by the fact that newer, high-resolution SD-OCT technology makes it possible to detect changes in the thickness of numerous retinal layers with a very high accuracy (12  $\mu\text{m}$ ). Aside from multiple other studies, we also have investigated the test-retest and inter-rater reliability of the SD-OCT machine. The results were consistent. All studies reported excellent inter- and intra-observer reliability for the assessment of the pRNFL using SD-OCT.<sup>3-6</sup> Additionally, a more recent study has shown that the newer segmentation algorithms, able to quantify more individual retinal layers, also show excellent reliability.<sup>7</sup>

Because the reliability of the technique is good, it is even more important to be aware of other potentially influencing factors, as the magnitude of these changes may exceed the degree of atrophy which can be reliably quantified in the eye of a patient suffering from MS. In [chapter 2.1](#) we prospectively investigated whether physiological variation could cause detectable changes in pRNFL thickness and macular volume in healthy human subjects as measured by SDOCT.

The results of this study clearly demonstrated that the pRNFL thickness and the total macular volume (TMV) changed significantly under physiological conditions. Importantly, the degree of thickness changes were clearly above the level of measurement noise of the OCT machine.<sup>4</sup> Since no invasive physiological or laboratory measures were obtained during this study, it was not possible to identify the responsible mechanisms. Subjects who performed physical exercise in this study were requested to refrain from drinking during the exercise period, possibly leading to a mild state of dehydration. Whereas dehydration would be expected to cause thinning of the pRNFL and TMV due to decreasing cell volumes, an increase in thickness was observed. This could be explained by the runners' electrolyte status, which may influence the cellular volume in the retina. With the data available in this study however, such a theory

could not be tested. Multiple other studies have also reported a significant degree of variability of retinal layer thicknesses.<sup>8-11</sup> Several hypotheses have been put forward, such as changes in blood flow, retinal metabolism, standing position, and finally, disease related factors. Although all hypothesis are feasible to some extent, the first is a particularly realistic hypothesis and this was further investigated by a re-analysis of our data. In this study, described in [chapter 2.2](#), we used new software to exclude all retinal blood vessel related segmentation artefacts and compared these data with the classical segmented data. The results showed however that these blood vessel artefacts masked, rather than caused, the observed physiological changes. Thus, as hyperaemia seemed a very unlikely explanation for the observed physiological changes, we explored whether oral hydration may be of importance in this matter. In the prospective study described in [chapter 2.3](#), we investigated whether oral hydration could cause shortterm retinal changes and if so, if they would exceed what could be expected from normal ageing. Firstly, the randomised trial using a 2hour hydration escalation protocol with three consecutive SD-OCT assessments showed that there were no significant differences of retinal layer thicknesses between the three groups at any time-point. Secondly, the 18month follow up study with two SD-OCT assessments revealed significant ageing related changes of the GCL.

Taken together, there is significant short-term variability of retinal layers caused by physiological variation, as well as longitudinal ageing-related changes over time. The physiological variation can however not be explained by diurnal or exercise induced changes in retinal blood flow, or hydration status. The jury is still out on which of the many hypotheses put forward (see above) can explain this reproducible phenomenon. At present, the practical advice from these studies is that in absence of strenuous physical exercise or dehydration retinal OCT can be reliably used in a routine clinical settings.

#### **Scan quality: OSCAR-IB criteria**

Evidently, in order to achieve the previously reported high accuracy and good reproducibility, an OCT scan has to be of sufficient quality. In [chapter 3.1](#), the measurement artefact due to misplacement of the measurement beam was investigated. The results clearly showed that misplacement of the laser resulted in such a large measurement artefact (95%CI  $\pm 9\mu\text{m}$ , maximum size of error  $42\mu\text{m}$ ) that it may easily mask recognition of pRNFL loss due to neuroaxonal degeneration in MS. Importantly, the study describes a sign (regional heterogeneity of ONL/OPL reflectivity) by which retrospective identification of the error has become possible. Given the magnitude of the potential measurement artefact, we believe recognition of this artefact is relevant for multicentre studies using OCT. Using this sign will lead to rejection of these scans, preventing the use of incorrect, distorted data.

Before publication of the measurement artefact described in chapter 3.1, a small set of OCT quality control criteria were published by others.<sup>12</sup> Inter-rater agreement based on these (restricted) quality control criteria was not satisfactory. We therefore aimed to revise the consensus quality control criteria, including the sign described in chapter 3.1 and other published measurement artefacts. The development process of the 'OSCAR-IB' criteria is described in [chapter 3.2](#). The set of seven criteria was tested by an international group of neuro(ophthalmo)logists and OCT experts. Using the criteria for evaluating scan quality increased the inter-rater agreement substantially, which is particularly important in a multi-centre setting. Improved agreement regarding the rejection of scans of insufficient quality will also be relevant for the overall success in detecting small degrees of neurodegeneration which may otherwise be masked by measurement noise. An important secondary advantage of the OSCAR-IB criteria is the increased awareness of pitfalls of the OCT operator. After an OCT scan is performed, measurement artefacts can be recognised, but most often can not be corrected retrospectively. Having knowledge of the potential pitfalls in advance, will lead to overall higher quality scans, as some artefacts (S, C, I, B) can be prevented at the moment of scanning.

The OSCAR-IB criteria were developed and validated in a large and heterogeneous cohort. In order to extend the use of these criteria, an external validation was needed. In [chapter 3.3](#), we aimed to test the practicability and reliability of the OSCAR-IB criteria in a worldwide multi-centre setting. Twenty independent raters from thirteen international OCT expert centres participated in the study. The results showed that the OSCAR-IB criteria proved to work even better than in the pilot study (chapter 3.2). A substantial level of agreement was reached (inter-centre kappa of 0.7). In order to investigate the agreement between centres, a training- and test-set of OCT scans were composed. The trainingset was designed to ensure the researcher/OCT operator gets familiar with the use of the OSCAR-IB criteria. The test-set is used to perform an examination, in order to test whether the application of the criteria is used correctly. OCT experts participating in this study agreed that making these sets of scans with more broadly available would be helpful in order to increase quality of OCT scans in future clinical OCT trials. We have therefore made the training- and test-set of this manuscript available online ([www.oscar-ib.org](http://www.oscar-ib.org)). This way, MS researchers, OCT operators and researchers at international OCT reading centres can get familiar with the OSCAR-IB criteria (trainingset), and perform an examination (testset) in order to obtain a OCT quality assessment certification.

To sum up, we believe that use of these validated quality control criteria is of major importance. Using the criteria will enhance reliability of the method, especially when used longitudinally and in multi-centre settings. Additionally, overall scan quality will increase due to awareness of pitfalls, reducing the amount of rejected scans.

## **CLINICAL CONSIDERATIONS: OCT IN LONGSTANDING MS**

### **Retinal layer thickness and clinical disability**

A consistent finding in patients with MS is thinning of the retina as assessed by OCT. Data on retinal layer thickness provides valuable information on the visual system in patients with MS. There are however good arguments that atrophy of certain retinal layers also reflects more global neuroaxonal degeneration of the CNS. Therefore, besides the relationships between visual function and OCT measures,<sup>13</sup> many studies have investigated the structure-function relationship between retinal layer thickness and clinical disability in MS. Although not part of this thesis, we also have investigated the relationship between retinal layer thickness and the expanded disability status scale (EDSS) score. Our findings showed that atrophy of the innermost retinal layers (pRNFL and GCC) was significantly and negatively associated with EDSS score, but only in eyes of MS patients without a history of ON. Consistent with our findings, many studies reported a significant negative correlation between pRNFL thickness and EDSS.<sup>14-23</sup> Yet, some studies did not confirm this finding in patients with progressive MS.<sup>24,25</sup> More recent reports including multiple retinal layers, reported significant inverse correlations between the mean pRNFL and macular thickness with EDSS, while the OPL thickness showed a significant positive correlation with EDSS score.<sup>26</sup> Likewise, Tatrai et al reported inverse correlations between the EDSS and the GCC and mean overall pRNFL.<sup>27</sup>

Overall, there is a clear structure-function association between clinical disability and retinal layer thickness in MS, suggesting that atrophy of especially the innermost retinal layers is indeed a reflection of global neuroaxonal degeneration of the CNS.

### **Retinal layer thicknesses and disease heterogeneity**

The disease course in MS is very heterogeneous and mechanisms of pathology may differ between these types. We therefore investigated in [chapter 4.1](#), the relationship between disease course heterogeneity, including benign MS, and retinal layer thicknesses in longstanding MS. This study demonstrated that retinal layer thicknesses, particularly of the innermost retinal layers (pRNFL, GCC), were significantly related to the heterogeneous disease course in MS, but only in MSNON eyes. We observed most severe atrophy of the innermost retinal layers in patients with SPMS. In PP and benign MS a relative preservation of these layers was observed, suggesting rather limited susceptibility to cerebral neuroaxonal degeneration in these disease types. This finding may be of relevance in future trials, using OCT as an outcome measure for neuroaxonal degeneration. The results of other previous studies exploring pRNFL thickness in different disease types were somewhat inconsistent. No differences in pRNFL thickness

were found between patients with PPMS and relapsing onset MS by some groups,<sup>19,24,28,29</sup> while others described significantly lower pRNFL thickness in progressive disease stages, compared with patients with RRMS or CIS.<sup>30-32</sup> The inconsistency of these results may be caused by the small sample sizes, especially of the progressive subgroups.

More recent studies comparing disease types using multiple retinal layers reported the most severe atrophy of the innermost layers in SPMS, followed by RRMS and PPMS,<sup>33,34</sup> although this trend was not reported by Albrecht et al, who reported that all MS subtypes had significant thinning of the pRNFL and the GCL and IPL.<sup>26</sup>

Besides the typical disease courses, 10 to 20% of all patient experience a relative mild clinical disease course, called benign MS (BMS). In our study, we observed significantly more thinning of the macular GCC and the pRNFL and pINL in typical MS, compared with BMS. Nevertheless, patients with BMS still revealed considerably more retinal atrophy than HC eyes. Finally, although retinal layer thickness of patients with BMS clearly differs from patients with typical MS, the data also revealed that OCT data should not be used solely to distinguish between a benign and a typical disease course.

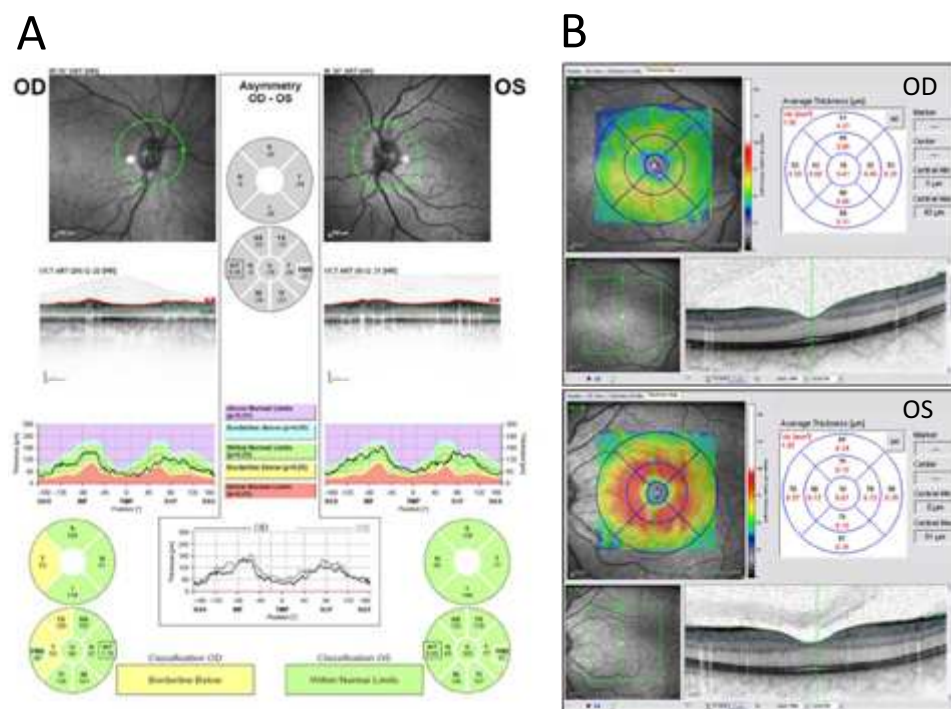
#### **Importance of (sub-)clinical episodes of optic neuritis**

Clearly, the anterior visual pathway is a frequent target of the MS disease process. Some studies have shown with postmortem analysis, that almost all patients with MS are expected to have typical changes in the retinal structures and optic nerve. Importantly, this was observed in eyes with and without a history of MSON.<sup>35</sup> In eyes with a known history of MSON, a certain degree of axonal degeneration is expected.<sup>24</sup> A recent meta-analysis confirmed this finding, but the authors also reported considerable thinning of the pRNFL in eyes of MS patients without a history of MSON.<sup>36</sup> Petzold et al investigated the pRNFL thickness of patients with MSON, patients with MSNON and healthy controls. They reported a mean decrease of 20.38  $\mu\text{m}$  (95% CI -22.86 to -17.91  $\mu\text{m}$ ) in MSON eyes, compared with HC eyes. Importantly, also in MSNON eyes a significant thinning of the pRNFL compared with HC (-7.08  $\mu\text{m}$ , 95% CI -8.65 to -5.52) was observed. To illustrate this, figure 1 shows the peripapillary ring scans (1A) and the macular volume scans (1B) of both eyes of a female patient with RRMS, who experienced an episode of ON in OD multiple years before scanning. The pRNFL (1A) as well as the macular GCC (1B) show substantial thinning in the affected eye (OD), compared with the unaffected eye (OS).

In chapter 4.1, clear differences between MS disease types were observed in MSNON eyes, but not in MSON eyes. This lack of difference in MSON eyes is probably due to the large impact of the experienced episode of ON on the retinal layers. The damage caused by the inflammatory lesion in the optic nerve will most probably have superseded the more subtle effects of the disease subtype.



These reports, together with the findings from chapter 4.1 have important implications for the use of OCT as an outcome marker for neurodegeneration in MS trials or patient management. Especially when used cross-sectionally, it is of major importance to take into account the history of ON, as an episode of ON will mask the more subtle changes caused by global neuroaxonal degeneration. Consequently, sub-clinical atrophy of the retinal layers in MSNON eyes are probably a better reflection of global CNS damage than the retinal layers in severely damaged MSON eyes.



**Figure 1.** (A) Peripapillary ring scans (both eyes) of a female RRMS patient with a history of ON in OD, but not in OS. The global mean pRNFL thickness is clearly less in the affected eye (OD, 84  $\mu\text{m}$ ) compared to the unaffected eye (OS, 103  $\mu\text{m}$ ). (B) Macular volume scan (both eyes, OD upper section, OS lower section) of a female RRMS patient with a history of ON in OD, but not in OS. The coloured thickness maps, together with the 1, 3, and 6 mm grids, show the thickness ( $\mu\text{m}$ ) of the ganglion cell complex (GCC) for every retinal sector. The affected eye (OD) shows severe thinning of the GCC compared to the unaffected eye (OS).

### Trans-synaptic axonal degeneration

Since the availability of newer segmentation software, it is possible to identify more individual retinal layers besides the pRNFL and TMV. Accordingly, new possibilities came up to investigate layer specific atrophy. Multiple studies have investigated this, and a consistent finding was the clear presence of atrophy of especially the innermost layers, the pRNFL and the macular GCL or GCC, in both eyes with and without history

of ON.<sup>26,27,34,37</sup> Data is however contradictory for the outermost layers which lie beyond the GCL, in particular the INL. In human retinal post-mortem samples, atrophy of the INL was demonstrated after about 20 years of disease duration.<sup>38</sup> Of the *in vivo* studies using OCT, only Saidha et al reported thinning of the INL and outer plexiform layer (OPL) in a subgroup of MSNON eyes and suggested this thinning was the results of a primary retinal process.<sup>39</sup> In contrast, several other studies reported preservation of the INL.<sup>26,40,41</sup>

Nevertheless, apart from the inconsistency regarding the retinal layers beyond the INL, multiple studies have shown that the innermost retinal layers are severely damaged in MSON eyes, but also, to a lesser extent, in MSNON eyes. In case of MSON eyes, it appears that the inflammatory lesion in the optic nerve causes chronic demyelination, eventually leading to axonal damage. This damage is then represented in the thickness of the pRNFL due to retrograde degeneration. The question is however, how it is possible that even MSNON eyes show, although less evident than in MSON eyes, significant thinning of the pRNFL and other inner retinal layers. Previous results from patients with a stroke suggest this thinning may be caused by retrograde *trans-synaptic* degeneration.<sup>42,43</sup>

The first experimental evidence for trans-synaptic axonal degeneration was first published by van Buren et al in 1963.<sup>44</sup> It is now understood that trans-synaptic axonal degeneration can occur following any damage to the CNS, and has therefore been suggested as a possible mechanism of spreading of neuroaxonal degeneration in MS.<sup>36,43</sup> There is early experimental data showing thinning of the retinal layers following optic nerve axotomy.<sup>45</sup> Acquired transsynaptic retrograde axonal degeneration however, has only recently been demonstrated in humans *in vivo*.<sup>42,43</sup>

This hypothesis of trans-synaptic degeneration as a mechanism by which neurodegeneration spreads to the CNS in MS, is strengthened by the consistent findings reported in [chapter 4.2](#) and other studies investigating the retinal layer atrophy in MS. All studies reported clear atrophy of the inner retinal layers (pRNFL, GCL), but a relative preservation of the more outer layers (OPL, ONL, ORLs) in MSNON eyes.<sup>26,37,40</sup> Chapter 4.2 reports extensive damage of the inner retinal layers, but almost no atrophy could be shown beyond the INL after an average disease duration of 20 years. This finding suggests that global damage in the CNS spreads towards the retina by retrograde trans-synaptic degeneration and that there may be a physiological barrier capable of halting this mechanism (the retinal INL). The rationale for such a physiological barrier might be that otherwise any form of trans-synaptic degeneration, if not stopped, could potentially spread through the human CNS, destroying all nerve cells eventually.

Chapter 4.2 describes the presence of retrograde trans-synaptic axonal degeneration, leading to retinal atrophy of the innermost layers. There is however also good evidence for this mechanism in the other direction; anterograde trans-synaptic

axonal degeneration. Interestingly, patients with a history of bilateral ON showed distinct, localised atrophy of the visual cortex, to a much larger extent than patients without any history of ON. This suggests that damage within the visual system causes not only retrograde (towards the retina), but also anterograde trans-synaptic axonal degeneration, leading to atrophy of at least V1 in the visual cortex.

### **Bi-directional trans-synaptic degeneration in the visual pathway**

In order to further investigate the presence of bi-directional trans-synaptic degeneration, the visual system is a suitable model. In [chapter 4.3](#) we have therefore explored the structure-structure relationship between damage to the posterior and anterior visual pathway, in order to explore the co-existence of antero- and retrograde trans-synaptic axonal degeneration in longstanding multiple sclerosis (MS). Besides, this study also investigated how damage of the visual system is associated with damage to the rest of the brain. Interestingly, this study provided evidence for the presence of both retrograde and anterograde transsynaptic axonal degeneration in the visual pathway of patients with MS. Additionally, it was demonstrated that thinning of the retinal pRNFL and GCC did not only reflect visual pathway damage, but was also related to global white and grey matter atrophy.

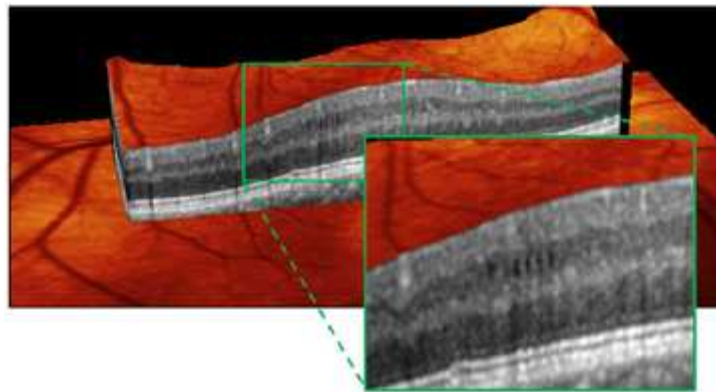
Regarding the visual pathway, the present findings are consistent with previous studies. Others have found that in patients with optic neuritis, the integrity of the optic radiations,<sup>46-48</sup> but also the visual cortex<sup>49,50</sup> revealed damage after episodes of ON. The present study extends on these studies however, by investigating individual retinal layers, the complete visual pathway *and* the global brain. Although no previous studies have explored these structures together, some studies have investigated the structurestructure relationship between retinal layer thickness and white and grey matter atrophy. Results were however inconsistent. In several studies, significant associations were found between pRNFL thickness and brain parenchymal fraction.<sup>16,20,22,51</sup> Associations with brain volume however, including multiple substructures, are still not entirely clear.<sup>16,18,20,22,52</sup> Two more recent studies using data on multiple segmented retinal layers showed the potential of this new segmented OCT as a measure for neuroaxonal degeneration, as they reported that retinal measures seem to reflect global central nervous system pathology in MS, with distinct retinal layers each associated with distinct CNS processes.<sup>53</sup> Additionally, Zimmermann et al described the pRNFL and GCL as parameters of neuroaxonal damage and were both linked to whole brain as well as white and grey matter atrophy.<sup>54</sup>

These data, together with the data from our study, suggest that trans-synaptic degeneration may not be restricted to the visual pathway and may disseminate through the whole brain. However, we believe that trans-synaptic degeneration is not solely

responsible for the observed relationships between retinal layer thickness and global brain atrophy. If it would be, a devastating 'domino-effect' would ensue affecting the entire brain. Therefore, the observed damage to the global brain might be more likely caused by a global mechanism affecting the entire brain, including the visual system. Taken together, the thickness of the pRNFL and GCC reflect damage of multiple components of the visual pathway, suggesting co-existence of bi-directional (trans-synaptic) degeneration. Additionally, retinal layer thickness also reflects global white and grey matter atrophy. If bi-directional trans-synaptic degeneration is responsible for the latter, or a more global mechanism, remains to be elucidated.

#### **MMO: a new MS phenotype, or a non-specific finding?**

Recently, a potentially new sign in MS was described by Gelfand et al.<sup>55</sup> This new sign, microcystic macular oedema (MMO<sup>a</sup>), is characterised by the presence of cystic areas of hyporeflectivity in the INL of the retina, visible on the OCT scan (Figure 2). These microcysts are associated with increased INL thickness, are more common in MSON eyes than in MSON eyes and are considered to indicate breakdown of the blood-retinal barrier.<sup>55,56</sup> The presence of MMO, and as a logical consequence also increased INL thickness, have shown to be associated with increased disability,<sup>55,56</sup> and some have even suggested MMO should be considered as a new MS phenotype.<sup>56</sup>



**Figure 2.** Microcystic macular oedema (MMO) in the left eye of an untreated male patient with RRMS. He had experienced an episode of ON in the affected eye 17 years ago. The MMO is characterised by several clear cystic areas of hyporeflectivity in the inner nuclear layer.

<sup>a</sup> Ironically, the American group who discovered this new sign published their first two papers in British Journals for which reason the most frequently used acronym has become MMO (from oedema) as opposed to MME (from edema). This linguistic prelude aside, MMO is a misnomer and the term "microcystic macular changes" has been suggested as an alternative [Kisimbi BRAIN 2013, Abegg BRAIN 2012].

Whereas the presence of MMO has shown to be related to disability in MS, it is important to note that it is not specific for MS. After evaluation of our own cohort of patients with longstanding MS (N=230), we found that the prevalence of MMO in longstanding MS (0.8%) was substantially lower than reported by others at an earlier disease phase.<sup>57</sup> More importantly however, we also reported a case of MMO in a patient with relapsing isolated optic neuritis, which indicates that MMO, although present in MS, is not specific for MS. This lack of specificity is further confirmed in a VUmc study by Burggraaff et al, where, besides refining and validating the diagnostic criteria for MMO, the clinical spectrum of MMO is discussed.<sup>58</sup> Burggraaff et al reported that the clinical spectrum of MMO is much broader than previously expected and that MMO was also present in age-related macular degeneration, epiretinal membranes, postoperative lesions, diabetic retinopathy, vascular occlusion, optic neuropathy, central serous chorioretinopathy, medication (interestingly not fingolimod) and miscellaneous causes.

Clearly, MMO is present in a broad range of diseases, but the aetiology remains unclear. The localisation of MMO is almost exclusively within the poorly vascularised INL of the perimacular rim, suggesting Müller cell pathology to be part of the cause of MMO, as Müller cells transverse through the entire retina with the bulk of their cell bodies in the INL. Moreover, the Müller cells are involved in maintaining the water homeostasis of the retina, possibly leading to formation of microcysts when dysfunctional. Experimental and clinical data however strongly suggest that MMO may be a result of neurodegeneration, through retrograde trans-synaptic degeneration.<sup>59,60</sup> If so, this would also explain the association between MMO and clinical disability and radiological disease activity.

Returning to the title of this paragraph, the presence of MMO has some predictive value in MS, but the precise cause and its clinical significance remain to be elucidated. We believe that one should be careful with considering MMO a new MS phenotype as MMO is clearly present in many other diseases besides MS, and clinical implications are still unknown. Longitudinal follow-up of patients with MMO may unravel the aetiology and clinical importance of this new clinical sign.

## **CONCLUSIONS**

Chapters 2 and 3 of this thesis investigated the methodological issues of the SD-OCT technique, while Chapter 4 focused on the clinical application of OCT in patients with longstanding MS.

The main conclusions of this thesis are:

- Retinal OCT is a reliable and accurate tool to quantify the thickness of individual retinal layers, but there is significant short-term variability of retinal layers caused by physiological variation.
- The use of quality control criteria increases scan quality and consequently enhances the reliability of the method, especially for longitudinal studies and in multi-centre settings.
- Only the innermost retinal layer thicknesses are associated with clinical disability and were associated with visual pathway and global brain damage, expectedly as a result of retrograde and anterograde transsynaptic degeneration.
- The INL of the retina appears to act like a physiological barrier to retrograde transsynaptic degeneration.
- The interpretation of OCT data in MS is critically dependent on knowledge of prior episode(s) of optic neuritis, because any subtle changes will be masked by the severe atrophy caused by the inflammatory lesion in the optic nerve.
- Microcystic macular oedema (MMO) in MS is more frequent in MS patients with a history of optic neuritis and is related to disability. MMO is however not specific for MS and the aetiology remains unknown.
- There is a need for future longitudinal studies to further substantiate the functional and structural relationships suggested by the published, mainly cross-sectional data.

## **FUTURE PERSPECTIVE**

In the past decade, retinal OCT has matured into a reliable and sensitive tool for assessing neuroaxonal degeneration in patients with MS and data on the subject is still rapidly accumulating. Especially with the development of new segmentation software, allowing segmentation of individual retinal layers, OCT is a promising tool for quantifying neuroaxonal degeneration in MS.

Currently, OCT is used in observational studies and clinical trials in MS. The most important future applications for OCT lie in monitoring disease progression over time in a clinical setting and assessing the degree of neuroaxonal degeneration in clinical trial settings. For the first, OCT can be of great value in monitoring subtle changes in neuroaxonal damage in patients with MS. The degree of neuroaxonal damage is not always in accordance with clinical outcomes, making a precise assessment tool more important. This assessment gives an objective impression of damage to the CNS, which can be of important predictive value regarding clinical disability in the future.

The fact that OCT can assess retinal layer thickness with a very high accuracy and reliability, is not painful or upsetting for the patient and is relatively quick, makes OCT a particularly useful tool to assess neuroaxonal degeneration in a clinical trial setting. In the coming years, many clinical trials with new neuro-protective, or even neuro-restorative agents will be performed. In these trials, QC controlled retinal OCT will enable the accurate and longitudinal assessment of the potential neuro-protective or neuro-restorative effect of these agents.

Future studies should focus on the collection of longitudinal OCT data. Whereas cross-sectional data on OCT has given important insights in structural differences between patients with MS and healthy controls and its relationship with clinical disability and brain pathology, longitudinal data is absolutely essential to explain the mechanisms underlying these relationships. Currently available longitudinal data is performed with the methodologically limited time-domain OCT and these data are not sufficient for demonstrating longitudinal associations between OCT and clinical disability. Therefore, longitudinal data with the more reliable SD-OCT, important because of the well recognised inter-eye and inter-subject differences, will help to investigate the predictive value of OCT on disease progression. Particularly the use of newer segmentation software enabling identification of the individual retinal layers, is a promising development and should be further investigated in larger and preferably longitudinal studies.

Besides the development of new software for SD-OCT machines, several improvements in OCT technology are being investigated. One of the promising new technologies is polarization-sensitive OCT (PS-OCT). PSOCT does not only detect the intensity, but also the polarization state of backscattered light from the retina. By detecting the birefringence and depolarisation of the different tissues, particularly highly structured ones, such as axons which are packed with a 9nm neuro-filament network, PSOCT yields depth-resolved information of the order of these structures. Therefore, PS-OCT may be a promising tool to investigate axonal pathology early, prior to ensuing atrophy.

In summary, since the application of OCT in MS two decades ago, new data and insights regarding the usefulness of OCT in the management of MS have accumulated. The technology evolves and improves quickly and the acquired insights, with high quality longitudinal data being available in the near future, will likely open a window for the investigation and unravelling of the mechanisms underlying neuroaxonal degeneration and related disability in patient suffering from MS.

## REFERENCES

1. Barkhof F, Calabresi PA, Miller DH, Reingold SC. Imaging outcomes for neuroprotection and repair in multiple sclerosis trials. *Nat Rev Neurol* 2009;5:256-266.
2. Frohman E, Costello F, Zivadinov R et al. Optical coherence tomography in multiple sclerosis. *Lancet Neurol* 2006;5:853-863.
3. Wolf-Schnurrbusch UEK, Ceklic L, Brinkmann CK et al. Macular thickness measurements in healthy eyes using six different optical coherence tomography instruments. *Invest Ophthalmol Vis Sci* 2009;50:34323437.
4. Balk LJ, Petzold A. Influence of the eye-tracking-based follow-up function in retinal nerve fiber layer thickness using fourier-domain optical coherence tomography. *Invest Ophthalmol Vis Sci* 2013;54:3045.
5. Huang JY, Pekmezci M, Yapple S, Lin S. Intra-examiner repeatability and agreement of corneal pachymetry map measurement by time-domain and Fourier-domain optical coherence tomography. *Graefes Arch Clin Exp Ophthalmol* 2010;248:1647-1656.
6. Serbecic N, Beutelspacher SC, Boul-Enein FC, Kircher K, Reitner A, Schmidt-Erfurth U. Reproducibility of high-resolution optical coherence tomography measurements of the nerve fibre layer with the new Heidelberg Spectralis optical coherence tomography. *Br J Ophthalmol* 2011;95:804-810.
7. Oberwahrenbrock T, Traber GL, Gabilondo I et al. Multicenter inter-rater reliability of retinal layer segmentation using spectral-domain OCT. *Submitted*.
8. Jo Y, Heo D, Shin Y, Kim J. Diurnal Variation of Retina Thickness measured with Time Domain and Spectral Domain Optical Coherence Tomography in Normal Subjects. *Invest Ophthalmol Vis Sci* 2011;52:6497-500.
9. Read SA, Collins MJ, Onso-Caneiro D. Diurnal variation of retinal thickness with spectral domain OCT. *Optom Vis Sci* 2012;89:611-619.
10. Tan CSH, Ngo WK, Chew MC, Li KZ, Lim LW, Sadda SR. Diurnal variation of retinal thickness measured by optical coherence tomography in normal adults. *Invest Ophthalmol Vis Sci* 2012;53:1639-1640.
11. de Kinkelder R, Kalkman J, Faber DJ et al. Heartbeat-induced axial motion artifacts in optical coherence tomography measurements of the retina. *Invest Ophthalmol Vis Sci* 2011;52:3908-3913.
12. Domalpally A, Danis RP, Zhang B, Myers D, Kruse CN. Quality issues in interpretation of optical coherence tomograms in macular diseases. *Retina* 2009;29:775-781.
13. Sakai RE, Feller DJ, Galetta KM, Galetta SL, Balcer LJ. Vision in multiple sclerosis: the story, structure-function correlations, and models for neuroprotection. *J Neuroophthalmol* 2011;31:362-373.
14. Albrecht P, Frohlich R, Hartung HP, Kieseier BC, Methner A. Optical coherence tomography measures axonal loss in multiple sclerosis independently of optic neuritis. *J Neurol* 2007;254:1595-1596.
15. Fisher JB, Jacobs DA, Markowitz CE et al. Relation of visual function to retinal nerve fiber layer thickness in multiple sclerosis. *Ophthalmology* 2006;113:324-332.
16. Gordon-Lipkin E, Chodkowski B, Reich DS et al. Retinal nerve fiber layer is associated with brain atrophy in multiple sclerosis. *Neurology* 2007;69:1603-1609.
17. Merle H, Olindo S, Donnio A, Richer R, Smadja D, Cabre P. Retinal peripapillary nerve fiber layer thickness in neuromyelitis optica. *Invest Ophthalmol Vis Sci* 2008;49:4412-4417.
18. Sepulcre J, Murie-Fernandez M, Salinas-Alaman A, Garcia-Layana A, Bejarano B, Villoslada P. Diagnostic accuracy of retinal abnormalities in predicting disease activity in MS. *Neurology* 2007;68:1488-1494.
19. Siepmann TAM, Bettink-Remeijer MW, Hintzen RQ. Retinal nerve fiber layer thickness in subgroups of multiple sclerosis, measured by optical coherence tomography and scanning laser polarimetry. *J Neurol* 2010;257:1654-1660.
20. Siger M, Dziegielewska K, Jasek L et al. Optical coherence tomography in multiple sclerosis: thickness of the retinal nerve fiber layer as a potential measure of axonal loss and brain atrophy. *J Neurol* 2008;255:1555-1560.
21. Toledo J, Sepulcre J, Salinas-Alaman A et al. Retinal nerve fiber layer atrophy is associated with physical and cognitive disability in multiple sclerosis. *Mult Scler* 2008;14:906-912.
22. Grazioli E, Zivadinov R, Weinstock-Guttman B et al. Retinal nerve fiber layer thickness is associated with brain MRI outcomes in multiple sclerosis. *J Neurol Sci* 2008;268:12-17.



23. Lange AP, Sadjadi R, Saeedi J, Lindley J, Costello F, Traboulsee AL. Time-Domain and Spectral-Domain Optical Coherence Tomography of Retinal Nerve Fiber Layer in MS Patients and Healthy Controls. *J Ophthalmol* 2012;2012:564627.
24. Henderson APD, Trip SA, Schlottmann PG et al. A preliminary longitudinal study of the retinal nerve fiber layer in progressive multiple sclerosis. *J Neurol* 2010;257:1083-1091.
25. Costello F, Hodge W, Pan YI, Eggenberger E, Freedman MS. Using retinal architecture to help characterize multiple sclerosis patients. *Can J Ophthalmol* 2010;45:520-526.
26. Albrecht P, Ringelstein M, Muller AK et al. Degeneration of retinal layers in multiple sclerosis subtypes quantified by optical coherence tomography. *Mult Scler* 2012;18:1422-1429.
27. Tatrai E, Simo M, Iljicsov A, Nemeth J, Debuc DC, Somfai GM. In vivo evaluation of retinal neurodegeneration in patients with multiple sclerosis. *PLoS One* 2012;7:e30922.
28. Henderson APD, Trip SA, Schlottmann PG et al. An investigation of the retinal nerve fibre layer in progressive multiple sclerosis using optical coherence tomography. *Brain* 2008;131:277-287.
29. Gelfand JM, Goodin DS, Boscardin WJ, Nolan R, Cuneo A, Green AJ. Retinal axonal loss begins early in the course of multiple sclerosis and is similar between progressive phenotypes. *PLoS One* 2012;7:e36847.
30. Oberwahrenbrock T, Schippling S, Ringelstein M et al. Retinal damage in multiple sclerosis disease subtypes measured by high-resolution optical coherence tomography. *Mult Scler Int* 2012;2012:530305.
31. Pulicken M, Gordon-Lipkin E, Balcer LJ, Frohman E, Cutter G, Calabresi PA. Optical coherence tomography and disease subtype in multiple sclerosis. *Neurology* 2007;69:2085-2092.
32. Costello F, Hodge W, Pan YI, Freedman M, DeMeulemeester C. Differences in retinal nerve fiber layer atrophy between multiple sclerosis subtypes. *J Neurol Sci* 2009;281:74-79.
33. Ratchford JN, Saidha S, Sotirchos ES et al. Active MS is associated with accelerated retinal ganglion cell/inner plexiform layer thinning. *Neurology* 2013;80:47-54.
34. Saidha S, Syc SB, Durbin MK et al. Visual dysfunction in multiple sclerosis correlates better with optical coherence tomography derived estimates of macular ganglion cell layer thickness than peripapillary retinal nerve fiber layer thickness. *Mult Scler* 2011;17:1449-1463.
35. Galetta KM, Calabresi PA, Frohman EM, Balcer LJ. Optical coherence tomography (OCT): imaging the visual pathway as a model for neurodegeneration. *Neurotherapeutics* 2011;8:117-132.
36. Petzold A, de Boer JF, Schippling S et al. Optical coherence tomography in multiple sclerosis: a systematic review and meta-analysis. *Lancet Neurol* 2010;9:921-932.
37. Balk LJ, Twisk JW, Steenwijk MD et al. A dam for retrograde axonal degeneration in multiple sclerosis? *J Neurol Neurosurg Psychiatry* 2014;85:782-9.
38. Green AJ, McQuaid S, Hauser SL, Allen IV, Lyness R. Ocular pathology in multiple sclerosis: retinal atrophy and inflammation irrespective of disease duration. *Brain* 2010;133:1591-1601.
39. Saidha S, Syc SB, Ibrahim MA et al. Primary retinal pathology in multiple sclerosis as detected by optical coherence tomography. *Brain* 2011;134:518-533.
40. Syc SB, Saidha S, Newsome SD et al. Optical coherence tomography segmentation reveals ganglion cell layer pathology after optic neuritis. *Brain* 2012;135:521-533.
41. Sriram P, Graham SL, Wang C, Yiannikas C, Garrick R, Klistorner A. Transsynaptic retinal degeneration in optic neuropathies: optical coherence tomography study. *Invest Ophthalmol Vis Sci* 2012;53:1271-1275.
42. Jindahra P, Petrie A, Plant GT. The time course of retrograde trans-synaptic degeneration following occipital lobe damage in humans. *Brain* 2012;135:534-541.
43. Jindahra P, Petrie A, Plant GT. Retrograde trans-synaptic retinal ganglion cell loss identified by optical coherence tomography. *Brain* 2009;132:628-634.
44. Van Buren JM. Trans-synaptic retrograde degeneration in the visual system of primates. *J Neurol Neurosurg Psychiatry* 1963;26:402-409.
45. Hollander H, Bisti S, Maffei L, Hebel R. Electroretinographic responses and retrograde changes of retinal morphology after intracranial optic nerve section. A quantitative analysis in the cat. *Exp Brain Res* 1984;55:483-493.

46. Ciccarelli O, Toosy AT, Hickman SJ et al. Optic radiation changes after optic neuritis detected by tractography-based group mapping. *Hum Brain Mapp* 2005;25:308-316.
47. Reich DS, Smith SA, Gordon-Lipkin EM et al. Damage to the optic radiation in multiple sclerosis is associated with retinal injury and visual disability. *Arch Neurol* 2009;66:998-1006.
48. Kolbe S, Bajraszewski C, Chapman C et al. Diffusion tensor imaging of the optic radiations after optic neuritis. *Hum Brain Mapp* 2012;33:2047-2061.
49. Audoin B, Fernando KT, Swanton JK, Thompson AJ, Plant GT, Miller DH. Selective magnetization transfer ratio decrease in the visual cortex following optic neuritis. *Brain* 2006;129:1031-1039.
50. Pfueller CF, Brandt AU, Schubert F et al. Metabolic changes in the visual cortex are linked to retinal nerve fiber layer thinning in multiple sclerosis. *PLoS One* 2011;6:e18019.
51. Dorr J, Wernecke KD, Bock M et al. Association of retinal and macular damage with brain atrophy in multiple sclerosis. *PLoS One* 2011;6:e18132.
52. Young KL, Brandt AU, Petzold A et al. Loss of retinal nerve fibre layer axons indicates white but not grey matter damage in early multiple sclerosis. *Eur J Neurol* 2013;20:803-811.
53. Saidha S, Sotirchos E, Oh J et al. Relationships Between Retinal Axonal and Neuronal Measures and Global Central Nervous System Pathology in Multiple Sclerosis. *Arch Neurol* 2012;1-10.
54. Zimmermann H, Freing A, Kaufhold F et al. Optic neuritis interferes with optical coherence tomography and magnetic resonance imaging correlations. *Mult Scler* 2013;19:443-450.
55. Gelfand JM, Nolan R, Schwartz DM, Graves J, Green AJ. Microcystic macular oedema in multiple sclerosis is associated with disease severity. *Brain* 2012;135:1786-1793.
56. Saidha S, Sotirchos ES, Ibrahim MA et al. Microcystic macular oedema, thickness of the inner nuclear layer of the retina, and disease characteristics in multiple sclerosis: a retrospective study. *Lancet Neurol* 2012;11:963-972.
57. Balk L, Killestein J, Polman C, Uitdehaag B, Petzold A. Microcystic macular oedema confirmed, but not specific for multiple sclerosis. *Brain* 2012;135:e226.
58. Burggraaff MC, Trieu J, de Vries-Knoppert WA, Balk L, Petzold A. The clinical spectrum of microcystic macular oedema. *Invest Ophthalmol Vis Sci* 2014;55:952-61.
59. Abegg M, Dysli M, Wolf S, Kowal J, Dufour P, Zinkernagel M. Microcystic macular edema: retrograde maculopathy caused by optic neuropathy. *Ophthalmology* 2014;121:142-149.
60. Petzold A. Microcystic macular oedema in MS: T2 lesion or black hole? *Lancet Neurol* 2012;11:933-934.