

# VU Research Portal

## New Applications of Bronchoscopic Techniques

Lee, P.

2014

### **document version**

Publisher's PDF, also known as Version of record

[Link to publication in VU Research Portal](#)

### **citation for published version (APA)**

Lee, P. (2014). *New Applications of Bronchoscopic Techniques*.

### **General rights**

Copyright and moral rights for the publications made accessible in the public portal are retained by the authors and/or other copyright owners and it is a condition of accessing publications that users recognise and abide by the legal requirements associated with these rights.

- Users may download and print one copy of any publication from the public portal for the purpose of private study or research.
- You may not further distribute the material or use it for any profit-making activity or commercial gain
- You may freely distribute the URL identifying the publication in the public portal ?

### **Take down policy**

If you believe that this document breaches copyright please contact us providing details, and we will remove access to the work immediately and investigate your claim.

### **E-mail address:**

[vuresearchportal.ub@vu.nl](mailto:vuresearchportal.ub@vu.nl)



available at [www.sciencedirect.com](http://www.sciencedirect.com)



journal homepage: [www.elsevier.com/locate/lungcan](http://www.elsevier.com/locate/lungcan)



# Primary lung cancer after treatment of head and neck cancer without lymph node metastasis: Is there a role for autofluorescence bronchoscopy?

Pyng Lee<sup>a,\*</sup>, Remco de Bree<sup>b</sup>, Hes A.P. Brokx<sup>a</sup>, C. René Leemans<sup>b</sup>,  
Pieter E. Postmus<sup>a</sup>, Tom G. Sutedja<sup>a</sup>

<sup>a</sup> Department of Pulmonary Diseases, VU University Medical Center, Amsterdam, The Netherlands

<sup>b</sup> Department of Otolaryngology/Head and Neck Surgery, VU University Medical Center, Amsterdam, The Netherlands

Received 10 December 2007; received in revised form 18 March 2008; accepted 28 March 2008

## KEYWORDS

Head and neck cancer;  
Lung cancer;  
Survival;  
Autofluorescence bronchoscopy

## Summary

**Background:** Head and neck cancer (HNC) is the 5th most common cancer worldwide. As good locoregional tumor control can be achieved with current treatment strategies, patients who develop second primary tumors from field cancerization have poorer prognosis.

**Objectives:** To determine if autofluorescence bronchoscopy (AF) played a role in the detection of second primary lung cancer (SPLC), and impact of SPLC on survival of patients with HNC and no cervical lymph node metastasis (N0).

**Methods:** Patients with HNC(N0) referred for symptoms and/or radiology suspicious for lung cancer were assessed with AF. Data on patient demographics, smoking, cancer characteristics, and outcome were prospectively collected.

**Results:** Fifty-one patients (44 males) with curatively treated HNC(N0) were evaluated. Median age was 70 years, all were current or former smokers of 35 pack years, and 25 had chronic obstructive lung disease. Over a median follow up of 60 months, 8 patients were diagnosed with synchronous and 26 with metachronous SPLC. Forty-two SPLC were found; 12 (29%) affected the tracheobronchial tree and 30 (71%) involved the lung parenchyma. Median time to metachronous SPLC was 22 months. Most of SPLC were surgically resectable. Five radiographically occult lung cancers detected by AF were successfully treated with endobronchial therapy. Lung cancer mortality was 24%. HNC patients who developed synchronous and metachronous SPLCs had significantly shorter survival (51 and 144 months) compared to those without (240 months) ( $p = 0.0005$ ).

**Abbreviations:** HNC, head and neck cancer; SPLC, second primary lung cancer; AF, autofluorescence; CXR, chest radiograph; CT, computed tomography; TNM system, tumor, node and metastasis system; NSCLC, non-small cell lung cancer; PET, positron emission tomography.

\* Corresponding author at: Department of Respiratory and Critical Care Medicine, Singapore General Hospital, Outram Road, Singapore 169608, Singapore. Tel.: +65 6321 4700; fax: +65 6227 1736.

E-mail address: [lee.pyng@sgh.com.sg](mailto:lee.pyng@sgh.com.sg) (P. Lee).

*Conclusion:* SPLC impacted negatively on the survival of patients with HNC. Close surveillance with AF and CT for SPLC combined with aggressive treatment of early stage lung cancer might be a strategy to improve outcome.

© 2008 Elsevier Ireland Ltd. All rights reserved.

## 1. Introduction

Head and neck cancer (HNC) is the 5th most common cancer worldwide, and is the most common neoplasm in Asia [1]. In the Netherlands, the total incidence of squamous cell carcinoma of the head and neck is about 2300 patients per year of which, 650 will die from it [2]. In the last decade, owing to better locoregional tumor control achieved with surgery and radiotherapy, more patients are at risk for second primary tumors [3]. These tumors often appear at unfavourable sites such as the lungs, esophagus and previously treated head and neck areas. Data from the Netherlands mirror the reported risk of 2–3% per year for second primary tumor with the majority occurring in the first 2 years [4–6].

Long term exposure to carcinogens namely tobacco smoke and alcohol causes field cancerization which can harbor many mutated cells and give rise to second primary or field tumors [7]. Patients with curatively treated HNC are followed regularly to facilitate early detection of locoregional recurrence to allow salvage surgery [8], and for second primary tumors. Although prospective data have not demonstrated significant survival benefit following treatment of asymptomatic recurrences or second primary lung cancers (SPLCs) detected during close surveillance [6,9,10], others have indicated better outcome for patients diagnosed early with limited disease who still retain the option for future intervention [11,12].

Our objectives were to evaluate role of autofluorescence bronchoscopy (AF) in the surveillance of patients with HNC and no cervical lymph node metastases (N0) treated with curative intent as well as to compare the outcome of those detected with synchronous and metachronous SPLC by AF and computed tomography (CT).

## 2. Patients and methods

### 2.1. Post-treatment surveillance of HNC by otolaryngologist

Post-treatment surveillance of HNC followed the guidelines of Dutch Head and Neck Cooperative Group where the patient was seen every 2 months in the 1st year; every 3 months in the 2nd year; every 4 months in the 3rd year; twice in the 4th and 5th years; and once yearly thereafter. These visits included detailed history, physical examination, indirect laryngoscopy and chest radiograph (CXR). If patients presented with cervical metastases or radiological pulmonary nodules after primary treatment, diagnostic work-up that included panendoscopy, CT and/or magnetic resonance imaging (MRI) was performed to exclude local recurrence or second primary tumor in the head and neck, lungs and esophagus. All routine and extra visits by patients who developed recurrence, SPLC and treatment were documented.

### 2.2. Post-treatment surveillance of HNC by pulmonologist

Included were patients with curatively treated squamous cell HNC(N0) who were referred to the pulmonary department for radiological abnormality and/or symptoms suspicious of lung cancer between 1995 and 2005, and prospectively followed until December 2006. All patients underwent conventional white light bronchoscopy and AF (LIFE® Xilix, BC, Richmond, Canada) to evaluate the tracheobronchial tree while CT was performed to detect lung parenchymal pathology. Subjects with radiographic abnormalities suspicious of lung cancers had histological confirmation of the neoplasms followed by appropriate staging and treatment. If pre-neoplastic lesions were found in the tracheobronchial tree, AF was repeated every 6 months for the duration of the study.

Staging of HNC and lung cancer was in accordance with the TNM classification system, and management based on a multi-disciplinary approach after considering results of staging procedures and patient's overall health status. All patients gave informed consent for AF, and the study protocol was approved by the institutional review board.

### 2.3. Definitions

A lung malignancy was classified as second primary tumor when it differed in histology from HNC squamous cell carcinoma. For lung cancers that were of the same histology, the criteria by Warren and Gates [13] had to be fulfilled: (1) each neoplasm must be geographically separate and distinct with 2 cm of normal appearing mucosa in between and (2) the possibility of metastasis excluded. Synchronous lung cancers were defined as those diagnosed at the same time or within 6 months of HNC, and metachronous as lung cancers that developed greater than 6 months later.

### 2.4. Statistics

Patient demographics, comorbidity, smoking history, cancer characteristics, time interval to second primary lung cancer, mode of detection and outcome were prospectively collected and entered into a database. Values were expressed as median, range and percentages. Comparison between two groups was performed with Mann–Whitney *U*-test, and survival was estimated by the Kaplan–Meier method. Differences in estimates between groups were assessed using the log rank test. Univariate and multivariate regression analyses were performed to identify prognostic factors. A *p*-value of <0.05 was considered statistically significant.

**Table 1** Patient demographics

No. of patients with HNC treated with curative intent	51
Oral cavity	3
Oropharynx	9
Hypopharynx	5
Larynx	34
Median age in years (range)	70 (63–79)
Gender (%)	
Male	44 (86%)
Female	7 (14%)
Smoking status (%)	
Current smoker	23 (45%)
Former smoker	28 (55%)
No. of pack years: median (range)	35 (30–45)
COPD (%)	25 (49%)
Median follow-up in months (range)	60 (29–96)
Median time to metachronous SPLC in months (range)	22 (8–63)

**Table 2** Cancer characteristics

No. of SPLC detected	42
Modality for SPLC detection	
AF	12 (29%)
CT	30 (71%)
Histology of SPLC	
Squamous cell carcinoma	31
Adenocarcinoma	6
Bronchoalveolar cell carcinoma	3
Large cell carcinoma	1
Small cell carcinoma	1
Stage distribution of SPLC	
Synchronous NSCLC ( <i>n</i> = 9)	
Stage 1A	3
Stage 1B	6
Metachronous NSCLC ( <i>n</i> = 32)	
Stage 0 (CIS)	5
Stage 1A	11
Stage 1B	10
Stage 2A	2
Stage 2B	1
Stage 3A	1
Stage 4	2
Metachronous small cell carcinoma (limited)	1

### 3. Results

#### 3.1. Patient characteristics (Table 1)

Fifty-one patients were recruited: 44 males and 7 females with median age 70 years (range, 63–79). All were current or former smokers of median 35 pack years (range, 30–45), and 25 patients had chronic obstructive lung disease according to American Thoracic Society criteria [14]. During the follow up of 60 months (range, 29–96), 8 patients developed synchronous and 26 patients metachronous SPLC. Twenty-six patients were diagnosed with 1 SPLC and eight patients with 2 SPLC. Median time to metachronous SPLC was 22 months (range, 8–63).

Pre-neoplastic lesions involving the tracheobronchial tree were detected using AF. Based on initial histology of biopsies taken from sites that demonstrated abnormal fluorescence, severe dysplasias were found in 4 patients, moderate dysplasia in 8 patients, low-grade dysplasia (mild dysplasia, squamous metaplasia, basal cell hyperplasia and chronic inflammation) in 12 patients, and normal histology in 17 patients.

#### 3.2. Cancer characteristics (Table 2)

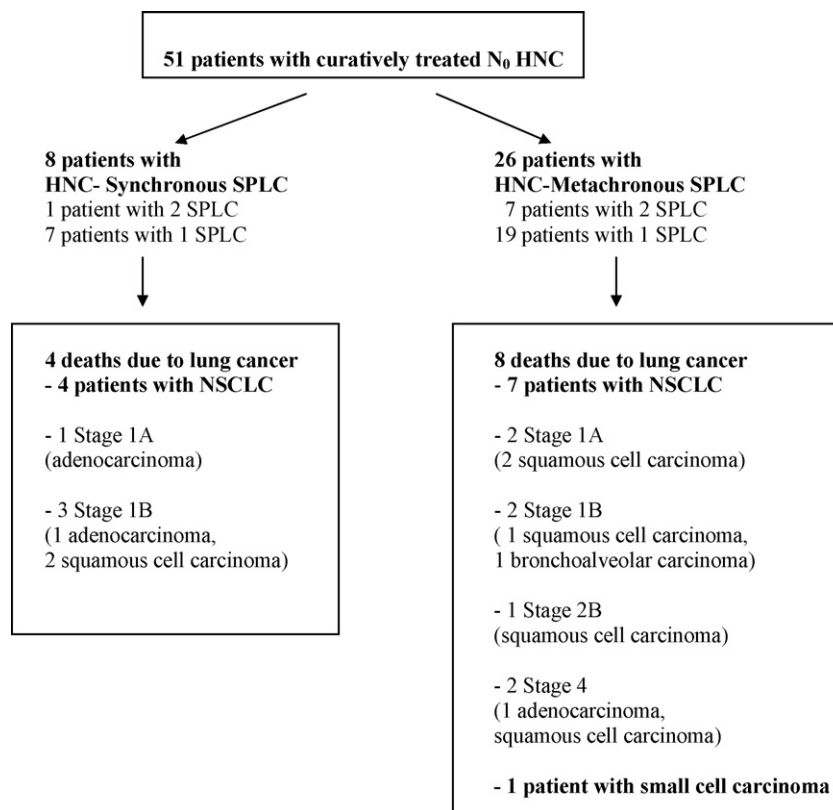
Forty-two SPLC were diagnosed; 12 SPLC by AF, and 30 SPLC by CT. Incorporating AF to the diagnostic evaluation led to the detection of synchronous SPLC at another site of the tracheobronchial tree in two patients due to abnormal fluorescence, which would otherwise be missed on conventional imaging. Thirty-eight SPLC (91%) were early stage cancers (stage 2B and below) of which 31 (82%) were treated with surgical resection. Five radiographically occult lung cancers (ROLC) with visible distal margins and each measuring 1 cm<sup>2</sup> were diagnosed by AF and successfully treated with endobronchial electrocautery. One patient with bi-lobar bronchioloalveolar carcinoma was considered inop-

erable due to underlying severe COPD. Histology of SPLC included squamous cell carcinoma (*n* = 31, 74%), adenocarcinoma (*n* = 6, 14%), bronchioloalveolar carcinoma (*n* = 3, 7%), large cell carcinoma (*n* = 1, 2.5%) and small cell carcinoma (*n* = 1, 2.5%).

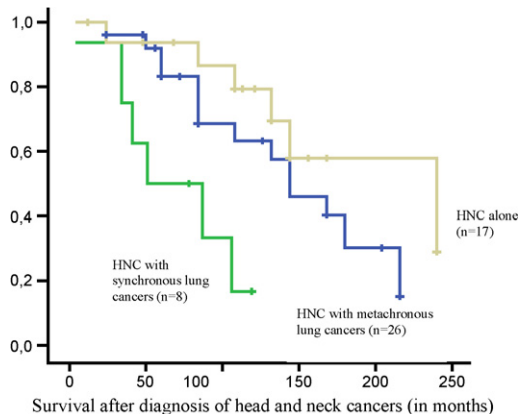
#### 3.3. Cancer related mortality, survival and gender differences (Figs. 1–3 and Table 3)

Twelve patients died of lung cancer, giving lung cancer related mortality of 24% (Fig. 1). Survival (Fig. 2) calculated in months from the diagnosis of HNC of patients with synchronous lung cancers was found to be significantly shorter (51 months) compared against those with metachronous lung cancers (144 months) and with HNC alone (240 months) (*p* = 0.0005). The discrepancy in outcome was still observed between subjects with synchronous versus metachronous SPLC when survival was adjusted in order to abolish lead-time bias, to measure from the time of diagnosis of SPLC NSCLC (stage 2 and below) till death (Fig. 3).

Patients with synchronous SPLC smoked more (51 pack years) than those with metachronous SPLC (35 pack years) (*p* = 0.025) but were similar in age (*p* = 0.14) and gender (*p* = 0.92) distribution as well as in their co-morbidity status (*p* = 0.62). Although four patients had local HNC recurrences, three died of underlying lung cancer. A similar observation was also found in those with synchronous NSCLC where 4 of the 6 deaths were due to lung cancer recurrences despite being early stage SPLC (1 stage 1A adenocarcinoma, 2 stage 1B squamous cell carcinomas and 1 stage 1B adenocarcinoma) treated with curative intent (Fig. 1). Another factor beside synchronous SPLC (*p* = 0.008) that influenced survival



**Fig. 1** Diagnosis of lung cancer in patients with head and neck cancers. HNC: head and neck cancer, SPLC: second primary lung cancer, NSCLC: non-small cell lung cancer.

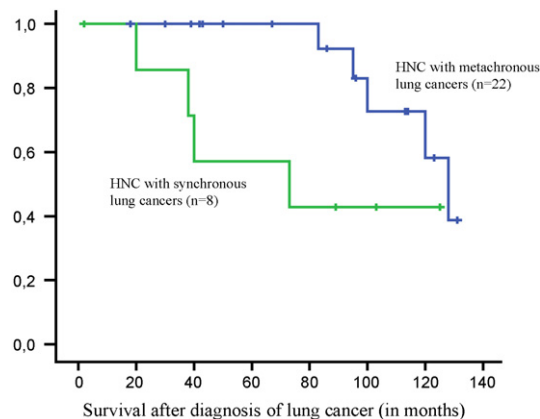


**Fig. 2** Survival comparison of patients with head and neck cancers alone versus those with SPLC (synchronous and metachronous). Survival of patients with synchronous SPLC was 51 months compared against 144 months for those with metachronous SPLC and 240 months for those without lung cancers ( $p=0.0005$ ), despite all synchronous SPLC were stage 1A and 1B.

was gender ( $p=0.013$ ) where females tended to have worse outcome (Table 3).

#### 4. Discussion

Patients with HNC are predisposed to develop second primary tumors of the aerodigestive tract. Field cancerization



**Fig. 3** Survival comparison between patients synchronous and metachronous SPLC (stage 2 and below). Median survival calculated from diagnosis of SPLC: synchronous SPLC was 73 months versus 128 months for metachronous SPLC ( $p=0.04$ ).

following exposure of the entire mucosa to carcinogenic insult may lead to the development of multiple foci of pre-malignant and malignant lesions [6] and within the head and neck regions, genetically altered cells can migrate extensively within the mucosa [15,16].

Metachronous second primary tumors occur more commonly in individuals who continue with excessive tobacco and alcohol consumption [17], and the development of second primary tumor which can occur in up to 30% of patients becomes increasingly important when their primary HNC can be effectively treated. As demonstrated in our study, second

**Table 3** Gender differences

	Males (n = 44)	Females (n = 7)	p-Value
<b>Patient characteristics</b>			
Median survival after HNC in months (range)	108 (69–165)	41 (24–113)	0.013*
Median age in years (range)	70 (63–79)	66 (58–73)	0.43
No. of pack years of smoking (range)	35 (30–46)	36 (30–40)	0.84
No. of patients with COPD (%)	22 (50%)	3 (43%)	0.78
No. of patients with SPLC (%)	29 (66%)	5 (71%)	0.82
No. of patients with synchronous SPLC	7 (16%)	1 (14%)	0.88
No. of patients with metachronous SPLC	22 (50%)	4 (57%)	0.86
Median time to SPLC in months (range)	25 (12–77)	9 (3–30)	0.15
Lung cancer related mortality	10/44	2/7	0.74
<b>Cancer characteristics</b>			
Histology of SPLC (n = 42)			
Squamous cell carcinoma	25	6	
Adenocarcinoma	6	0	
Bronchoalveolar carcinoma	3	0	
Large cell carcinoma	1	0	
Small cell carcinoma	1	0	
Stage of SPLC			
0	1	4	
1A	13	1 (died)	
1B	15	1 (died)	
2A	2		
2B	1		
3A	1		
4	2		
Limited small cell	1		

\* $p < 0.05$ .

primary cancer has a negative impact on the overall survival with lung and esophageal cancers carrying worse prognosis [5,18,19]. Therefore, it seems logical for patients with HNC to undergo regular post-treatment surveillance to allow early detection of local recurrence or second primary cancer when they are asymptomatic. However, prospective data have not demonstrated survival benefit with CXR screening [11,12], and surveillance with endoscopic evaluation of the upper aerodigestive tract remains controversial. A meta-analysis reveals an apparent 2.5-fold increase in tumor yield with panendoscopy [19], which has led some to advocate for interval endoscopic examination within 2 years of HNC treatment, while others recommend limiting these procedures to patients who develop symptom and who continue to smoke [20].

To our knowledge, our study is the first that investigates the complementary role of AF to routine bronchoscopy for the evaluation of curatively treated HNC(N0) patients who developed symptoms and radiological abnormalities suspicious of SPLC. Overall AF detected 29% (12/42) of SPLC, all were ROLC of which 5, demonstrating visible distal margins and each measuring 1 cm<sup>2</sup> were successfully treated with endobronchial electrosurgery. Moreover, AF identified synchronous tracheobronchial cancers in two patients, which necessitated a change in treatment strategy from lobectomy to bilobectomy.

It is not surprising that patients with HNC who develop SPLC have worse outcome than those without. However,

our study also demonstrated that patients with synchronous SPLC fared poorly compared to those with metachronous SPLC when survival was adjusted in both groups to measure from the time of SPLC diagnosis.

Patients with synchronous SPLC smoked more cigarettes, which could suggest that heavy smokers with HNC were more likely to develop SPLC early. In fact, one study found that an independent prognostic factor for the development of second primary tumor after successful treatment of early stage laryngeal cancer was the amount of cigarettes smoked [21]. Bach et al. also demonstrated significant risk variation for lung cancer among smokers, with 50 and 8% of lung cancers occurring in the highest and lowest risk quartiles, respectively [22].

Our study suggested that the female gender could be another factor impacting survival as they seemed to have worse outcome than their male counterparts following the development of SPLC which were all squamous cell carcinomas. Although we acknowledge that their representation was too small to make any meaningful conclusion, however differences in tumor biology more frequently observed in women such as increased p53 gene mutation, higher levels of adduct formation, increased CYP1A1 expression, decreased DNA repair capacity and increased K-ras gene mutations as well as the causative role of estrogen in tumorigenesis may predispose the female gender further to the carcinogenic effects of cigarette smoking [23,24].

Clearly smoking cessation is most important in reducing cancer risk however lung cancer continues to be diagnosed in former smokers with dismal outcome promoting a need to diagnose lung cancer early by means of screening or surveillance of high risk individuals. AF complements this strategy as it is a sensitive tool for the detection of pre-neoplastic lesions and early cancers of the bronchial mucosa, which can occur in the tracheobronchial tree due to chronic tobacco exposure [25,26]. Unlike white light bronchoscopy that uses light reflectance to define structural features of the bronchial epithelium, AF depends on the concentration of fluorophores in the tissue to discriminate normal from abnormal areas. Normal bronchial epithelium fluoresces in green when illuminated but as it transforms through dysplasia, carcinoma in situ to invasive cancer, a progressive reduction in green and a corresponding increase in red fluorescence occurs due to increased epithelial thickness and tumor neovascularisation [27].

HNC patients diagnosed with synchronous SPLC have worse outcome, which may lend impetus to incorporating AF into the staging work-up of patients diagnosed with HNC that are amenable to curative treatment. Moreover, application of AF in our study led to the identification of synchronous tracheobronchial cancers, which were otherwise undetectable by CT necessitating a change in management. In recent years, positron emission tomography (PET)/CT has demonstrated superiority over CT and MRI not only in assessing tumor invasion of surrounding anatomical structures, occult cervical nodal and distant metastases but also in the early detection of synchronous SPLC [28–30] thus, these imaging modalities can be applied for initial staging HNC, and interval PET/CT and AF for post-treatment surveillance of curatively treated HNC(N0) patients.

The study has several limitations. We acknowledge that without cytogenetic analysis, it is difficult to differentiate SPLC from pulmonary metastasis with certainty, however the risk of distant metastasis is strongly dependent on the presence of lymph node metastasis and since all patients had N<sub>0</sub> disease, it could be assumed that these cancers were true SPLC. The second limitation is the small sample size however it is the first study that incorporates AF in the evaluation and follow-up of patients with HNC. Our study demonstrated that AF facilitated the detection of 5 ROLC, which were successfully managed with bronchoscopic treatment, and in two patients, synchronous airway cancerous lesions that led to a change in surgical strategy. It is also the first report that demonstrates significant survival differences among HNC patients with synchronous and metachronous SPLC after adjusting for lead-time bias.

## 5. Conclusion

Our study confirms the results of others where HNC patients without nodal metastasis do well until they develop second primary tumor, which can occur anywhere in the aerodigestive tract. Although panendoscopy is controversial, our study shows that AF impacts management up to a third of patients with HNC(N0) referred for symptoms and/or radiological abnormalities suspicious of lung cancer. Notwithstanding that our sample size is small, it is noteworthy that despite curative surgery, four patients with early stage synchronous

SPLC (3 stage 1B and 1 stage 1A) died of lung cancer recurrence. It is arguable that some “synchronous SPLC” which shared the same histology as HNC could in fact be pulmonary metastases, however it is difficult to differentiate without cytogenetic analysis. PET/CT performed at the initial staging might provide the necessary data to confirm the latter especially if nodal and distant metastases are detected. Moreover, standard uptake value of SPLC measured by PET could further stratify patients with stage 1 NSCLC into the most appropriate treatment protocols to improve outcome [31,32].

## Conflict of interest

All authors have none declared.

## References

- [1] Sankaranarayanan R, Masuyer E, Swaminathan R, Ferlay J, Whelan S. Head and neck cancer: a global perspective on epidemiology and prognosis. *Anticancer Res* 1998;18(6B): 4779–86.
- [2] Vereniging van Intergrale Kankercentra (VIKC), Utrecht. URL: <http://www.ikcnet.nl>.
- [3] Dhooge IJ, De Vos M, Van Cauwenberge PB. Multiple primary malignant tumors in patients with head and neck cancer: results of a prospective study and future perspectives. *Laryngoscope* 1998;108(2):250–6.
- [4] Dikshit RP, Boffetta P, Bouchardy C, Merletti F, Crosignani P, Cuchi T, et al. Risk factors for the development of second primary tumors among men after laryngeal and hypopharyngeal carcinoma. *Cancer* 2005;103(11):2326–33.
- [5] Licciardello JT, Spitz MR, Hong WK. Multiple primary cancer in patients with cancer of the head and neck: second cancer of the head and neck, esophagus, and lung. *Int J Radiat Oncol Biol Phys* 1989;17(3):467–76.
- [6] Buwalda J, Zuur CL, Lubsen H, Tijssen JG, Koole R, Hordijk GJ. Annual chest X-ray in patients after treatment for laryngeal or oral cancer: only a limited number of second primary lung cancers detected. *Ned Tijdschr Geneesk* 1999;143(29): 1517–22.
- [7] Braakhuis BJ, Tabor MP, Kummer JA, Leemans CR, Brakenhoff RH. A genetic explanation of Slaughter’s concept of field cancerization: evidence and clinical implications. *Cancer Res* 2003;63(8):1727–30.
- [8] Davidson J, Briant D, Gullane P, Keane T, Rawlinson E. The role of surgery following radiotherapy failure for advanced laryngopharyngeal cancer. A prospective study. *Arch Otolaryngol Head Neck Surg* 1994;120(3):269–76.
- [9] Ritoe SC, Krabbe PF, Jansen MM, Festen J, Joosten FB, Kaanders JH, et al. Screening for second primary lung cancer after treatment of laryngeal cancer. *Laryngoscope* 2002;112(11): 2002–8.
- [10] Ritoe SC, Krabbe PF, Kaanders JH, van den Hoogen FJ, Verbeek AL, Marres HA. Value of routine follow-up for patients cured of laryngeal carcinoma. *Cancer* 2004;101(6):1382–9.
- [11] Boysen M, Lovdal O, Tausjo J, Winther F. The value of follow-up in patients treated for squamous cell carcinoma of the head and neck. *Eur J Cancer* 1992;28(2–3):426–30.
- [12] Haas I, Hauser U, Ganzer U. The dilemma of follow-up in head and neck cancer patients. *Eur Arch Otorhinolaryngol* 2001;258(4):177–83.
- [13] Warren S, Gates O. Multiple primary malignant tumors: a survey of the literature and a statistical study. *Am J Cancer* 1932;51:1358–403.

- [14] Standards for the diagnosis and care of patients with chronic obstructive pulmonary disease. American Thoracic Society. *Am J Respir Crit Care Med* 1995;152:577–121.
- [15] Braakhuis BJ, Tabor MP, Leemans CR, van der Wal JE, Snow GB, Brakenhoff RH. Second primary tumors and field cancerization in oral and oropharyngeal cancer: molecular techniques provide new insights and definitions. *Head Neck* 2002;24(2):198–206.
- [16] Tabor MP, Brakenhoff RH, Ruijter-Schippers HJ, Van der Wal JE, Snow GB, Leemans CR, et al. Multiple head and neck tumors frequently originate from a single preneoplastic lesion. *Am J Pathol* 2002;161(3):1051–60.
- [17] Brouha X, Tromp D, Hordijk GJ, Winnubst J, De Leeuw R. Role of alcohol and smoking in diagnostic delay of head and neck cancer patients. *Acta Otolaryngol* 2005;125(5):552–6.
- [18] Do KA, Johnson MM, Lee JJ, Wu XF, Dong Q, Hong WK, et al. Longitudinal study of smoking patterns in relation to the development of smoking-related secondary primary tumors in patients with upper aerodigestive tract malignancies. *Cancer* 2004;101(12):2837–42.
- [19] Haughey BH, Gates GA, Arfken CL, Harvey J. Meta-analysis of second malignant tumors in head and neck cancer: the case for an endoscopic screening protocol. *Ann Otol Rhinol Laryngol* 1992;101(2 Pt 1):105–12.
- [20] Benninger MS, Shariff A, Blazoff K. Symptom-directed selective endoscopy: long-term efficacy. *Arch Otolaryngol Head Neck Surg* 2001;127(7):770–3.
- [21] Narayana A, Vaughan AT, Fisher SG, Reddy SP. Second primary tumors in laryngeal cancer: results of long-term follow-up. *Int J Radiat Oncol Biol Phys* 1998;42(3):557–62.
- [22] Bach PB, Kattan MW, Thornquist MD, Kris MG, Tate RC, Barnett MJ, et al. Variations in lung cancer risk among smokers. *J Natl Cancer Inst* 2003;95(6):470–8.
- [23] Patel JD. Lung cancer in women. *J Clin Oncol* 2005;23(14):3212–8.
- [24] Shriver SP, Bourdeau HA, Gubish CT, Tirpak DL, Davis AL, Luketich JD, et al. Sex-specific expression of gastrin-releasing peptide receptor: relationship to smoking history and risk of lung cancer. *J Natl Cancer Inst* 2000;92(1):24–33.
- [25] Hirsch FR, Prindiville SA, Miller YE, Franklin WA, Dempsey EC, Murphy JR, et al. Fluorescence versus white-light bronchoscopy for detection of preneoplastic lesions: a randomized study. *J Natl Cancer Inst* 2001;93(18):1385–91.
- [26] Lam S, Kennedy T, Unger M, Miller YE, Gelmont D, Rusch V, et al. Localization of bronchial intraepithelial neoplastic lesions by fluorescence bronchoscopy. *Chest* 1998;113(3):696–702.
- [27] Pasic A, Vonk-Noordegraaf A, Risse EK, Postmus PE, Sutedja TG. Multiple suspicious lesions detected by autofluorescence bronchoscopy predict malignant development in the bronchial mucosa in high risk patients. *Lung Cancer* 2003;41(3):295–301.
- [28] Ha PK, Hdeib A, Goldenberg D, Jacene H, Patel P, Koch W, et al. The role of positron emission tomography and computed tomography fusion in the management of early-stage and advanced-stage primary head and neck squamous cell carcinoma. *Arch Otolaryngol Head Neck Surg* 2006;132(1):12–6.
- [29] Schoder H, Yeung HW, Gonen M, Kraus D, Larson SM. Head and neck cancer: clinical usefulness and accuracy of PET/CT image fusion. *Radiology* 2004;231(1):65–72.
- [30] Zanation AM, Sutton DK, Couch ME, Weissler MC, Shockley WW, Shores CG. Use, accuracy, and implications for patient management of [18F]-2-fluorodeoxyglucose-positron emission/computerized tomography for head and neck tumors. *Laryngoscope* 2005;115(7):1186–90.
- [31] Pillot G, Siegel BA, Govindan R. Prognostic value of fluorodeoxyglucose positron emission tomography in non-small cell lung cancer: a review. *J Thorac Oncol* 2006;1(2):152–9.
- [32] Potti A, Mukherjee S, Petersen R, Dressman HK, Bild A, Koontz J, et al. A genomic strategy to refine prognosis in early-stage non-small-cell lung cancer. *N Engl J Med* 2006;355(6):570–80.