

VU Research Portal

New Applications of Bronchoscopic Techniques

Lee, P.

2014

document version

Publisher's PDF, also known as Version of record

[Link to publication in VU Research Portal](#)

citation for published version (APA)

Lee, P. (2014). *New Applications of Bronchoscopic Techniques*.

General rights

Copyright and moral rights for the publications made accessible in the public portal are retained by the authors and/or other copyright owners and it is a condition of accessing publications that users recognise and abide by the legal requirements associated with these rights.

- Users may download and print one copy of any publication from the public portal for the purpose of private study or research.
- You may not further distribute the material or use it for any profit-making activity or commercial gain
- You may freely distribute the URL identifying the publication in the public portal ?

Take down policy

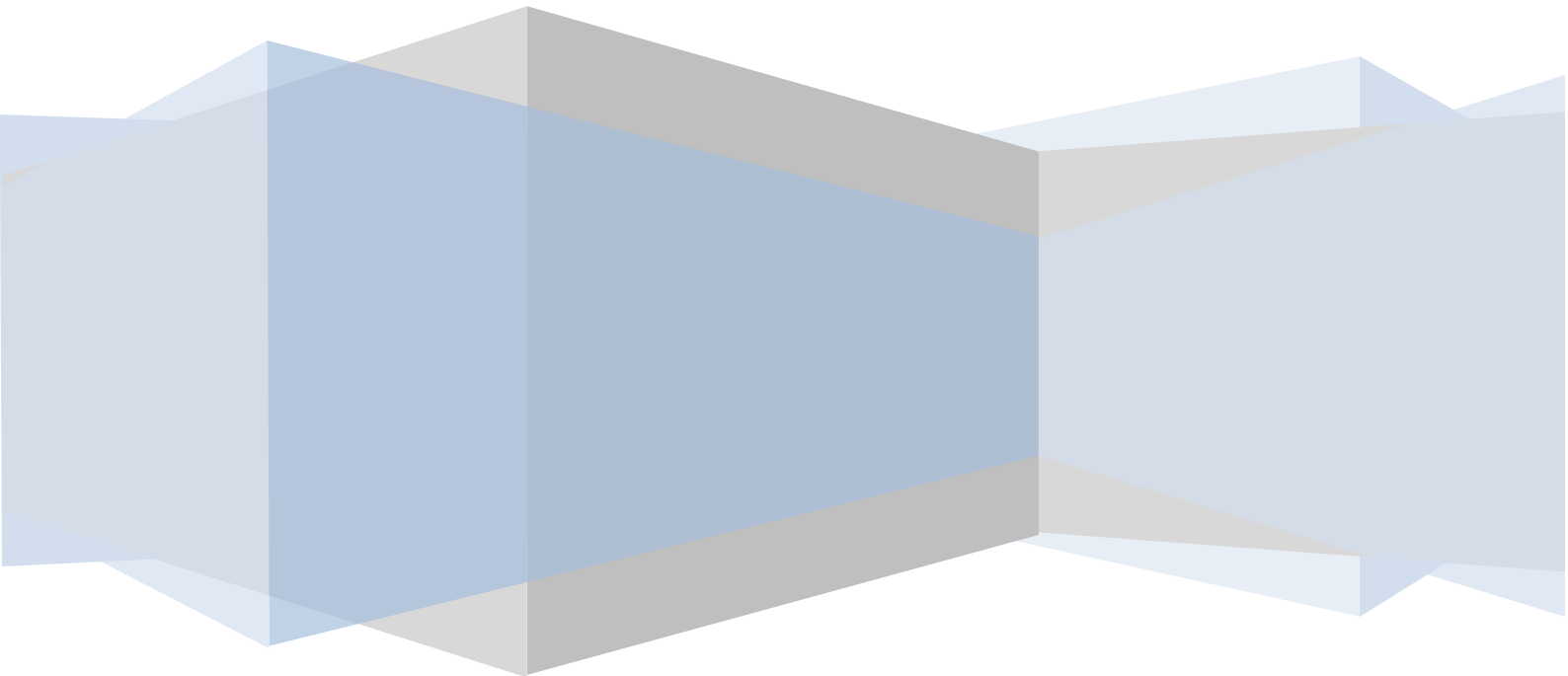
If you believe that this document breaches copyright please contact us providing details, and we will remove access to the work immediately and investigate your claim.

E-mail address:

vuresearchportal.ub@vu.nl

NEW APPLICATIONS OF BRONCHOSCOPIC TECHNIQUES

Pyng Lee MD



NEW APPLICATIONS OF BRONCHOSCOPIC TECHNIQUES

Pyng Lee MD

VRIJE UNIVERSITEIT

NEW APPLICATIONS OF BRONCHOSCOPIC TECHNIQUES

ACADEMISCH PROEFSCHRIFT

ter verkrijging van de graad Doctor aan
de Vrije Universiteit Amsterdam,
op gezag van de rector magnificus
prof.dr. F.A. van der Duyn Schouten,
in het openbaar te verdedigen
ten overstaan van de promotiecommissie
van de Faculteit der Geneeskunde
op dinsdag 16 december 2014 om 9.45 uur
in de aula van de universiteit,
De Boelelaan 1105

door

Pyng Lee

geboren te Singapore, Singapore

promotor: prof.dr. P.E. Postmus
copromotor: dr. T.G. Sutedia

CHAPTERS

1. Introduction

Early detection of lung cancer

2. Lee P, Sutedja TG. Lung Cancer Screening: is there any progress? Computed Tomography and Autofluorescence Bronchoscopy. *Curr Opin Pulm Med.* 2007; 13:243-8.
3. Lee P, Brokx HA, Postmus PE, Sutedja TG. Dual Digital Video-Autofluorescence Imaging for Detection of Pre-neoplastic Lesions. *Lung Cancer* 2007;58:44-9.
4. Lee P, Brokx HA, De Bree R, Leemans C. René, Postmus PE, Sutedja TG. Primary Lung Cancer after Treatment of Head and Neck Cancer without Lymph Node Metastasis: Is There A Role for Autofluorescence Bronchoscopy? *Lung Cancer* 2008;62:309-15.
5. Lee P, Van den Berg RM, Lam S, Gazdar AF, Grunberg K, McWilliams A, LeRiche J, Postmus PE, Sutedja TG. Color Fluorescence Ratio for Bronchial Dysplasia and Carcinoma-in-situ. *Clin Can Res* 2009;15:4700-5.
6. Lee P, Eberhardt R, Seet JE, Herth FJ. Videobronchoscopy for bronchial pre-neoplasia and early central airway cancer: a prospective randomized study.(submitted)
7. Lee P. Autofluorescence Bronchoscopy and Narrow Band Imaging. Principles and Practice of Interventional Pulmonology. Herth and Ernst (editors). In press.

New diagnostic techniques

8. Kunst PW, Lee P, Paul MA, Senan S, Smit EF. Restaging of the Mediastinum with Transbronchial Needle Aspiration after Chemotherapy and Radiotherapy. *J Thorac Oncol* 2007; 2:663-70.
9. Phua GC, Rhee KJ, Koh M, Loo CM, Lee P. A Strategy to Improve the Yield of Transbronchial Needle Aspiration. *Surgical Endoscopy* 2010; 24:2105-9.
10. Lee P, Low SY, Liem HL, Tan D, Eng P. Endobronchial Ultrasound for Detection of Tracheomalacia from Chronic Compression by Vascular Ring. *Respirology* 2007;12:299-301.
11. Lee P, Colt HG. Bronchoscopy for Lung Cancer: Appraisal of Current Technology and for the Future. *J Thorac Oncol* 2010;5:1290-300.

12. Summary in Dutch and in English

Curriculum vitae

Chapter 1

General Introduction and Outline of Thesis

INTRODUCTION

Since the invention of the flexible bronchoscope by Shigeto Ikeda and its introduction into clinical practice 40 years ago, bronchoscopy has evolved into the most commonly used diagnostic and therapeutic procedure, and is performed by pulmonologists, thoracic surgeons, critical care specialists, otolaryngologists, anesthesiologists and pediatric pulmonologists [1-3]. The flexible bronchoscope with its enhanced flexible distal tip allows the bronchoscopist to visualize all segmental bronchi with ease while a larger working channel with better accessory instruments increase its diagnostic and therapeutic armamentarium.[4]

Modifications of the standard flexible bronchoscope to the thin bronchoscope allows direct visualization of 8th through 12th generation bronchi not usually seen with standard bronchoscope, it also facilitates endotracheal intubation in challenging situations such as trauma, hemorrhage or head and neck deformities. The ultrathin bronchoscope which has an outer diameter of 1.8 mm, a flexible tip and a channel for biopsy, enables researchers to examine directly bronchioles, perform alveolobronchography as well as study bronchial epithelial cells collected from airways, which were previously inaccessible.[5]

Due to rapid advances achieved in video-chip technology, videobronchoscopy has replaced fiberoptic bronchoscopy more than a decade ago, which facilitated bronchoscopy teaching and better documentation of endoscopic images. The addition of color chip technology has also improved image quality, together with ultrasound and laser probes, zoom technology, and computerized processing give rise to endobronchial ultrasound (EBUS), endocytoscopy, confocal microendoscopy (μ cosm), optical coherence tomography (OCT), and endoscopic magnetic resonance tomography in an attempt to assess cellular morphology, depth of endobronchial lesions and beyond as well as associated mediastinal abnormality with greater precision and accuracy. In lung cancer, bronchoscopy remains pivotal in diagnosis, staging and symptom palliation of patients presenting with malignant central airway obstruction. Novel bronchoscopic imaging improves detection and localization of pre-invasive lesions of airway cancers for treatment. For peripheral lung nodules that are beyond the visibility of the bronchoscope, navigational methods and endobronchial ultrasonography facilitate accurate targeting. As bronchoscopy provides access to the airways and the lungs, it can be a tool for researchers to understand lung carcinogenesis, discover biomarkers for early detection and prognostication as well as assess tumor response to targeted therapy by means

of in-vivo microdynamic imaging.[6-8]. The thesis describes new applications of bronchoscopic techniques to pulmonary disease and lung cancer as technology evolves.

REFERENCES

- 1) Ikeda S, Yanai N, Ishikawa S. Flexible bronchofiberscope. Keio J Med. 1968;17:1-16.
- 2) Edell ES. Future therapeutic procedures. Chest Surg.Clin.N.Am 1996;6:381-95.
- 3) Ahmad M, Dweik RA. Future of flexible bronchoscopy. Clin.Chest Med. 1999;20:1-17.
- 4) Lee P, Kupeli E, Mehta AC. Therapeutic Bronchoscopy in Lung Cancer: Laser Therapy, Electrocautery Brachytherapy, Stents and Photodynamic Therapy. Clinics in Chest Medicine 2002; 23:241-256.
- 5) Tanaka M, Satoh M, Kawanami O, et al. A new bronchofiberscope for the study of diseases of very peripheral airways. Chest 1984; 85:590-594.
- 6) Ohtani K, Lee A, Lam S. Frontiers in bronchoscopic imaging, Respirology 2012;17:261-9.
- 7) Hanna WC, Yasufuku K. Bronchoscopic staging of lung cancer. Ther Adv Respir Dis 2013;7:111-8.
- 8) True LD, Gao X. Quantum dots for molecular pathology: their time has arrived. J Mol.Diagn. 2007;9:7-11.

Chapter 2

Lung Cancer Screening: is there any progress?
Computed Tomography and Autofluorescence
Bronchoscopy.

Curr Opin Pulm Med. 2007; 13:243-8.

Pyng Lee, Tom G Sutedja.

Department of Pulmonary Medicine
VU University Medical Center, Amsterdam, The Netherlands

Chapter 3

Dual digital video-autofluorescence imaging for detection of pre-neoplastic lesions

Lung Cancer 2007;58:44-9

Pyng Lee, Hes AP Brokx, Pieter E Postmus, Tom G Sutedja.

Department of Pulmonary Medicine
VU University Medical Center, Amsterdam, The Netherlands

Chapter 4

Primary Lung Cancer after Treatment of Head and Neck Cancer without Lymph Node Metastasis: Is There A Role for Autofluorescence Bronchoscopy?

Lung Cancer 2008;62:309-15.

Pyng Lee, Remco de Bree, Hes AP Brokx, Rene Leemans, Pieter E Postmus, Tom G Sutedja.

Departments of Pulmonary Medicine, Otolaryngology/ Head and Neck Surgery
VU University Medical Center, Amsterdam, The Netherlands

Chapter 5

Color Fluorescence Ratio for Bronchial Dysplasia and Carcinoma-in-situ.

Clinical Cancer Research 2009;15:4700-5

Pyng Lee,¹ Remco van den Berg,¹ Stephen Lam,³ Adi Gazdar,⁴ Katrien Grunberg,² Annette McWilliams,³ Jean Le Riche,³ Pieter E Postmus,¹ Tom G Sutedja¹

Departments of Pulmonary Medicine,¹ Pathology²
VU University Medical Center, Amsterdam, The Netherlands

BC Cancer Agency, Vancouver, British Columbia, Canada ³

University of Texas Southwestern Medical Center, Dallas, Texas ⁴

Chapter 6

Videobronchoscopy for bronchial pre-neoplasia and early central airway cancer: a prospective randomized study

Submitted to Lung Cancer

Pyng Lee,¹ Ralf Eberhardt,² Seet Ju Ee,³ Felix J Herth.²

Departments of Pulmonary Medicine,¹ Pathology³
National University Hospital, Singapore

Department of Pneumology and Critical Care Medicine Thoraxklinik,²
University of Heidelberg, Germany

Chapter 7

Autofluorescence Bronchoscopy and Narrow Band Imaging.

Principles and Practice of Interventional Pulmonology. Herth and Ernst (editors), Chapter 21;217-226.

Pyng Lee,

Division of Respiratory and Critical Care Medicine, National University Hospital

Chapter 8

Restaging of the Mediastinum with Transbronchial Needle Aspiration after Chemotherapy and Radiotherapy

Journal of Thoracic Oncology 2007;
2:663-70

Peter W Kunst,¹ Pyng Lee,¹ Marinus A Paul,² Suresh Senan,³ Egbert F Smit¹

Departments of Pulmonary Medicine,¹ Surgery,² Radiation Oncology³
VU University Medical Center, Amsterdam, The Netherlands

Chapter 9

Strategy to Improve the Yield of Transbronchial Needle Aspiration

Surgical Endoscopy 2010; 24:2105-9.

Ghee-Chee Phua, KJ Rhee, Mariko Koh, Chian-Min Loo, Pyng Lee

Department of Respiratory and Critical Care Medicine, Singapore General Hospital, Singapore

Endobronchial Ultrasound for Detection of Tracheomalacia from Chronic Compression by Vascular Ring

Respirology 2007;12:299-301

Pyng Lee, Su-Ying Low, HL Liem, Diana Tan, Philip Eng

Department of Respiratory and Critical Care Medicine, Singapore General
Hospital, Singapore

Bronchoscopy for Lung Cancer: Appraisal of Current Technology and for the Future.

Journal of Thoracic Oncology 2010;
5:1290-300

Pyng Lee, Henri G Colt

Division of Respiratory and Critical Care Medicine, National University
Hospital

Summary in Dutch and in English

SUMMARY/SAMENVATTING

In this thesis new applications of bronchoscopic techniques are described. In the first and main part of this thesis the potential use of this technique for early detection of lung cancer and the possible improvements of it are evaluated in a number of studies. In the second part some other aspects for bronchoscopic use in specific situations are described. The most important reason to detect lung cancer at an early stage is its poor outcome in general however the tool(s) to screen need to be sensitive to have impact on survival. In Chapter 2 a review of these aspects is given and the practical aspects are discussed. A new technique, autofluorescence bronchoscopy (AFB), that might have more promise than sputum cytology for early central airway lesions, is discussed. It has much higher specificity than white light bronchoscopy (WLB) and the advantage that it might be combined with treatment of the occult endobronchial cancers. The most important disadvantage is the character of the procedure: it is invasive. AF is superior over WL bronchoscopy in the detection of airway dysplasia but has difficulty distinguishing bronchitis, previous biopsy and airway fibrosis from pre-invasive lesions, resulting in longer procedural time and need for additional sedation which may compromise patient safety, increase the risk of bronchospasm, and bleeding from multiple endobronchial biopsies. In chapter 3, we used the dual system with simultaneous WLB and AFB. This resulted in shorter procedure time and the bronchoscopist is targeting the appropriate sites reflected in better sensitivity and specificity for detecting preneoplastic lesions.

In chapter 4 AFB was used in a group of patients with a high risk of developing lung cancer. Field cancerization is a well-known phenomenon in head and neck cancer patients. Although secondary primary lung cancers were mainly found in the parenchyma (71%) in this group of 51 patients the use of AFB affected the management in 1/3 of the cases. It detected 5 radiologically occult lung cancers and changed the surgical approach in 2 others.

In chapter 5 a new approach to improve AFB is described. AFB is more sensitive than WLB for detecting early (pre-)neoplastic lesions but the low specificity still makes it necessary that an excessive number of biopsies has to be taken. By adding the color fluorescence ratio R/G to AFB at 0.54 the sensitivity and specificity became 85% and 80% respectively for detecting early preneoplastic lesions. Adding this R/G ratio during the procedure to the visual score improved the specificity further to 88%.

AFB is more sensitive than WLB for detecting early neoplastic and pre-neoplastic lesions. WLB performed in these studies was by fiberoptic bronchoscopes, however these

have during the last decade been replaced by videobronchoscopes. Whether the superiority of AFB over white light detection with fiberoptic bronchoscopes is also applicable to videobronchoscopes was investigated in chapter 6. It was found that the videobronchoscope mode of AFB, the autofluorescence-reflectance imaging, was comparable to white light videobronchoscopy (WLVB) for detection of the early neoplastic and preneoplastic lesions. WLVB detected better bronchitis and by that prevented unnecessary biopsies of those areas.

In chapter 7 an overview of available techniques and future developments for bronchoscopic detection are described.

New techniques with widespread applications in lung cancer and pulmonary diseases have become on the market. In chapter 8 a rather old approach, transbronchial needle aspiration (TBNA), was used in patients for restaging after chemoradiotherapy prior to surgery. For 71% of the patients this technique achieved the correct diagnosis and made further staging of the mediastinum unnecessary. Critical for the success of TBNA is proper training and preparation of the obtained material.

In chapter 9, we set out to determine if conventional TBNA yield could be improved with training of bronchoscopists and assistants, standardization of technique, TBNA needle and specimen preparation. Post intervention TBNA yield was further compared against endobronchial ultrasound (EBUS) guided sampling with linear or radial probe EBUS. Conventional TBNA yield doubled from 43% (without intervention) to 82% (post-intervention). For lymph nodes measuring less than 2cm, EBUS was found to be more useful. Although EBUS is primarily used for the detection of lymph nodes it may have a role in other situations. In chapter 10 an example of this is described. Tracheomalacia due to chronic compression by a vascular ring was found which might be helpful for preoperative evaluation and decision making in this situation.

Bronchoscopy is a technique with extensive challenges and potential for improvement as is outlined in chapter 11.

Samenvatting

In dit proefschrift worden nieuwe toepassingen van bronchoscopische technieken beschreven. In het eerste en belangrijkste deel van dit proefschrift wordt de het mogelijke gebruik van deze techniek voor vroegdetectie van longkanker en de mogelijke verbeteringen geëvalueerd in een aantal studies. In het tweede deel worden enkele andere toepassingen van bronchoscoopie in specifieke situaties beschreven.

De belangrijkste reden om longkanker vroeg te willen ontdekken is het slechte resultaat van behandeling in het algemeen. Echter de technieken gebruikt voor screening

moeten effect hebben op overleving. In hoofdstuk 2 worden deze aspecten geëvalueerd en een aantal praktische consequenties besproken. Een nieuwe techniek is autofluorescentie bronchoscopie (AFB), dit heeft mogelijk meer potentie dan sputumcytologie voor het detecteren van vroege afwijkingen in de centrale luchtwegen. Het heeft een veel hogere specificiteit dan wit licht (WLB) bronchoscopie en het voordeel is dat het gecombineerd kan worden met behandeling van occulte endobronchiale tumoren. Het grootste nadeel van de techniek is het invasieve karakter. AF is veel beter dan WLB voor het detecteren van dysplasie in de luchtwegmucosa, maar het is moeilijk om het onderscheid te maken met bronchitis, plaatsen van eerdere biopsten en fibrosing van pre-invasieve lesies. Dit zorgt er voor dat de procedure vaak langer duurt met de noodzaak van extra sedatie waardoor de veiligheid van de patiënt in het gedrang kan komen, onder andere door meer bronchospasme en bloeding vanuit multipale biopsieplaatsen. In hoofdstuk 3 werd het bronchoscopie-systeem met simultaan WLB en AFB geëvalueerd. Dit resulteerde in een kortere tijd voor de procedure. Bovendien blijkt dat de bronchoscopist beter de juiste plaatsen biopsteert met als gevolg een betere sensitiviteit en specificiteit voor het detecteren van premaligne laesies.

In hoofdstuk 4 bij een groep patiënten met een hoog risico op het ontwikkelen van long kanker AFB toegepast om premaligne afwijkingen te vinden. Veldcarcinogenese is een bekend verschijnsel bij patiënten met hoofd-hals tumoren. Hoewel de meeste secundaire primaire longtumoren werden gevonden in het longparenchym in deze groep patiënten (n=51) en veel minder in het gebied dat met AFB kan worden onderzocht, blijkt het resultaat van AFB het beleid bij 1/3 van deze patiënten te beïnvloeden. Er werden 5 röntgenologisch occulte tumoren gevonden en het chirurgisch beleid werd aangepast in 2 andere patiënten. In hoofdstuk 5 wordt een nieuwe benadering om AFB te verbeteren beschreven om daarmee te voorkomen dat er een excessief aantal biopsten moet worden genomen. Door de R/G ratio in de fluorescentie toe te voegen bleek dat bij een ratio van 0,54 de sensitiviteit en specificiteit voor het detecteren van vroege premaligne afwijkingen verbetert tot 85% respectievelijk 80%. Als tijdens de procedure dit wordt toegevoegd aan de visuele interpretatie dan verbetert de specificiteit verder tot 88%.

Omdat de fiberbronchoscoop de afgelopen jaren vervangen is door de videobronchoscoop (VB) is het de vraag of de meerwaarde van AFB net zo groot is als het vergeleken wordt met wit licht VB (WLVB). In hoofdstuk 6 wordt de videobronchoscopie variant van AFB, autofluorescentie-reflectance imaging, vergeleken met WLVB. Er blijkt geen duidelijk verschil tussen beide te zijn voor het detecteren van premaligne en vroeg maligne afwijkingen. WLVB detecteert bronchitis beter en daardoor worden zijn er minder

biopten nodig. In hoofdstuk 7 worden de bestaande technieken en mogelijk toekomstige ontwikkelingen beschreven.

Nieuwe technieken met grootschalige toepassingen voor longkanker en ander longziekten zijn de afgelopen jaren op de markt gekomen. In hoofdstuk 8 wordt een tamelijk oude techniek, transbronchiale naald aspiratie (TBNA), geëvalueerd tijdens restadierung na chemoradiotherapie voor chirurgie. In 71% werd hiermee de juiste diagnose gesteld en was verdere stadierung van het mediastinum niet nodig. Kritisch voor het succes van TBNA is training en verwerking van het verkregen materiaal. In hoofdstuk 9 wordt dit geëvalueerd en blijkt er een verbetering te zijn van de opbrengst van 43% naar 82%. Vervolgens wordt dit ook vergeleken met het gebruik van EBUS (endobronchiale ultrasound met een lineaire of radiale sonde) en dan blijkt dat dit nog verder verbetert waarbij vooral de opbrengst van puncties uit name kleine lymfklieren (< 2 cm) groter is. Hoewel EBUS vooral gebruikt wordt voor het detecteren van lymfklieren, blijkt het ook mogelijk EBUS toe te passen voor totaal andere afwijkingen. In hoofdstuk 10 wordt een patiënt beschreven met tracheomalacie ten gevolge van een vasculaire ring, met EBUS was het mogelijk dit aan te tonen. Tenslotte wordt in hoofdstuk 11 een overzicht gegeven van de vele mogelijkheden van bronchoscopie.

ACKNOWLEDGEMENTS/ DANKWOORD

It is with happiness, and at the same time relief to be finally defending my PhD on 16 Dec 2014. It has indeed been a long but rewarding academic journey.

It has been a tremendous privilege to work alongside my promoter Professor PE Postmus who has been encouraging, nurturing, supportive and constructive for my thesis; co-promoter Dr Tom Sutedja whom I have learned a great deal in the field of early lung cancer detection/ intervention, and novel bronchoscopic imaging techniques.

In Singapore I would like to thank Professor Soo KC for his immense support in procuring funding for my PhD through the National Medical Research Council Grant. Following my defense, I will then be the first respiratory physician in Singapore with PhD, and my deepest gratitude for his belief in me. My husband Adrian who although stayed behind in Singapore due to work commitments stood by me for 1.5 years with daily video skype, and 2 trips to Amsterdam; my parents and sisters who will share my joy (in Singapore) on this special day.

Being a foreigner, I am very blessed to have made good friends even though my stay in Amsterdam was short; 2 of whom are my paranymphs: Hes and Frances. Other friends to be mentioned include Peter Kunst, Maya, Remco, Bas, Helen, Batt, and Louis. Colleagues at VUMC were most patient and accommodating towards me, speaking in English whenever I was around at meetings, conferences, presentations and day to day conversations, and with ease since the Dutch are natural linguists.

Living and working on my PhD in Amsterdam was special, and I was quickly infected by the habits of the Dutch. One which I cherish is being direct and liberal in thought, biking around town, cheese, tulips, and the inspirational art of Rembrandt and Van Gogh. Although it is with regret I have not mastered the Dutch language to defend my thesis I believe English defense by a physician from Singapore would be a first for pulmonary medicine at VUMC. It is with sincere gratitude to Professor Postmus for his outstanding translation of the summary to Dutch, and to friends and colleagues for making time to celebrate this special day with me.

Bedankt,

Pyng

Curriculum Vitae

Pyng Lee MD is an Associate Professor of Yong Loo Lin School of Medicine, National University of Singapore. She is also Director of Interventional Pulmonology, Senior Consultant of the Division of Respiratory and Critical Care Medicine, National University Hospital. She is competent in pulmonary and critical care medicine, interventional bronchoscopy, pleuroscopy and other advanced bronchoscopic techniques. Her training in rigid bronchoscopy, pleuroscopy, endobronchial ultrasonography, autofluorescence bronchoscopy, bronchial thermoplasty and bronchoscopic volume reduction techniques was accomplished during her attachments at the Cleveland Clinic USA; University of California Irvine, USA, Universitat Llobret, Barcelona, Spain; Hiroshima City Hospital, Japan, Thoraxklinik, Heidelberg, Germany; and Vrije University Medical Center, Amsterdam, The Netherlands.

Pyng Lee has an active interest in lung cancer, pleural disease, obstructive airway disease, interventional bronchoscopy and pleuroscopy. She is the Global Governor for Singapore at the American College of Chest Physicians. She is also the Regent for Singapore at the World Association of Bronchology and Interventional Pulmonology. She was the past President of the Singapore Thoracic Society, and serves on International Scientific Committees for Lung Cancer and Interventional Pulmonology as well as American Thoracic Society and American College of Chest Physician Steering Committees. She is invited locally and overseas to speak and instruct on pleuroscopy, bronchoscopy, lung cancer, pleural disease, bronchoscopic volume reduction techniques and bronchial thermoplasty.

Pyng Lee is the author of publications in peer-reviewed journals has written a manual on Step by Step to Flex-rigid Pleuroscopy. She also co-edited the Atlas of Thoracoscopy and Pleuroscopy which was named Best Book in Internal Medicine by the British Medical Association in 2011.

She is keen for research, and holds research grants on lung cancer, malignant pleural effusion and severe bronchial asthma. She received the Young Investigator's Award in 2000 for discovery of a new asthma index that separates moderate from severe asthma, Best Poster Award in 2006 at CHEST for research in talc and cancer cells, Best Original Investigation and Presentation Award in 2014 at Chest World Congress for pioneering work in confocal laser microendoscopy, and the Geoffrey McLennan Award conferred by the American Association for Bronchology and Interventional Pulmonology for advancing the field of interventional pulmonology in Asia. At home, she was named Best Teacher in 2011, and recently received the 2014 NUHS Teaching Excellence Award.

SELECTED PUBLICATIONS

1. Lee P, Mak KH, Ling ML, Cheng SK, Koh TH. Haemophilus Parainfluenza Infective Endocarditis. Ann Acad Med Singapore 1996;25:761-2.
2. Lee P, Goh SK, Yap WM, Chan CC. A Case Report of Aspergillus Hypersensitivity Syndrome with Obstructing Bronchial Aspergillosis. Ann Acad Med Singapore 2000;29:246-8.
3. Lee P, Chee CBE, Wang YT. Questionnaire Survey on Management of Spontaneous Pneumothorax. Singapore Med J 2000;41:538-41.
4. Lee P, Chee CB, Wang YT. An Asymptomatic Right Tracheobronchial Mass on Chest Radiograph. CHEST 2001;119:1582-5.
5. Lee P, Abisheganaden J, Chee CB, Wang YT. A New Index that Predicts Near-fatal Asthma. Eur Respir J 2001;18:272-8.
6. Lee P, Tai DY. Clinical Features of Patients with Acute Organophosphate Poisoning requiring Intensive Care. Intensive Care Med 2001;27:694-9.
7. Lee P, Culver DA, Mehta AC. Case Report on Syndrome of Iron Pill Aspiration. Chest 2002;121:1355-7.
8. Lee P, Gildea TR, Stoller JK. Emphysema in non-smokers: Alpha 1 antitrypsin deficiency and other causes. Cleve Clin J Med 2002;69:928-46.
9. Lee P, Ray SL, Colt HG. Survey of Pulmonologists' Perspectives on Thoracoscopy. Journal of Bronchology 2003;10:99-106. **Editorial**
10. Lee P, Minai OA, Mehta AC, DeCamp M, Murthy S. Pulmonary Nodules in Lung Transplant Recipients: Etiology and Outcome. Chest 2004;125:165-72.
11. Lee P, Yap WS, Pek WY, Ng AWK. An Audit of Medical Thoracoscopy and Talc Poudrage for Pneumothorax Prevention in Advanced Chronic Obstructive Pulmonary Disease. CHEST 2004; 125:1315-1320. **Editorial CHEST 2004;125:1190-2.**
12. Lee P, Mehta AC. Management of Obstructing Airway Lesions in Patients with Lung Cancer for PCCU 2004, Volume 18, Lesson 5.
13. Lee P, Colt HG. Rigid and Semirigid Pleuroscopy: the Future is Bright. Respiriology 2005;10:418-25.
14. Pernafiel A, Lee P, Hsu AAL, Eng P. Topical Mitomycin-C for Obstructing Endobronchial Granuloma. Ann Thorac Surg 2006;82:e22-3.

15. Lee P, Hsu A, Lo C, Colt HG. Prospective Evaluation of Flex-rigid Pleuroscopy for Indeterminate Pleural Effusion: Accuracy, Safety and Outcome. *Respirology* 2007;12:881-6.
16. Lee P, Colt HG. State of the Art: Pleuroscopy. *J Thorac Oncol.* 2007;7:663-70.
17. Lee P, Colt HG. Spray catheter technique for pleural anesthesia: a novel method for pain control before talc poudrage. *Anesth Analg.* 2007;104:198-200.
18. Lee P, PE Postmus, Sutedja TG. CT Screening for lung Cancer. *N Engl J Med* 2007;356:745.
19. Lee P, Sutedja TG. Lung Cancer Screening: is there any progress? *Computed Tomography and Autofluorescence Bronchoscopy.* *Curr Opin Pulm Med.* 2007; 13:243-8.
20. Lee P, Brokx HA, Postmus PE, Sutedja TG. Dual Digital Video-Autofluorescence Imaging for Detection of Pre-neoplastic Lesions. *Lung Cancer* 2007;58:44-9.
21. Lee P, Postmus PE, Sutedja TG. Bronchoscopy in Lung Cancer. *European Respiratory Disease Issue II, October 2007.*
22. Toh CK, Lee P, Chowbay B, Goh JW, Mancer K, Tan PH. An Inflammatory Response with worsening of Pleural Effusion on Treatment with erlotinib in non-small cell lung cancer. *Acta Oncol.* 2007; 46:256-8.
23. Kunst PW, Lee P, Paul MA, Senan S, Smit EF. Restaging of the Mediastinum with Transbronchial Needle Aspiration after Chemotherapy and Radiotherapy. *J Thorac Oncol* 2007; 2:663-70.
24. Lee P, Low SY, Liem HL, Tan D, Eng P. Endobronchial Ultrasound for Detection of Tracheomalacia from Chronic Compression by Vascular Ring. *Respirology* 2007;12:299-301.
25. Lee P, Vonk-Noordegraaf A, Paul MA, Sutedja TG. An Unusual Manifestation of Riedel's Thyroiditis. *Ann Thorac Surg* 2007;84:300.
26. Lee P, Sutedja TG. Population screening for lung cancer using CT. *Thorax* 2008;63:87.
27. Lee P, Brokx HA, De Bree R, Leemans C. René, Postmus PE, Sutedja TG. Primary Lung Cancer after Treatment of Head and Neck Cancer without Lymph Node Metastasis: Is There A Role for Autofluorescence Bronchoscopy? *Lung Cancer* 2008;62:309-15.
28. Lee P, Loo CM, Raghuram J, Colt HG. Survey of Bronchoscopy Practice in Singapore. *J Bronchology and Interventional Pulmonology* 2008; 15:215-20.

29. Chay WY, Penafiel A, Raghuram J, Chua KL, Loo CM, Lee P. Dyspnea in a transplant recipient with pulmonary nodules. *CHEST* 2009;135:860-5.
30. Lee P, Van den Berg RM, Lam S, Gazdar AF, Grunberg K, McWilliams A, LeRiche J, Postmus PE, Sutedja TG. Color Fluorescence Ratio for Bronchial Dysplasia and Carcinoma-in-situ. *Clin Can Res* 2009;15:4700-5.
31. Lee P, Mehta AC, Mathur PN. Management of Complications from Diagnostic and Interventional Bronchoscopy. *Respirology* 2009;14:940-53.
32. Lee P, Cheah FK, Huang J, Poon D, Loo CM. A Suspicious Clot. *Thorax* 2009;64:1011.
33. Lee P, Mathur PN, Colt HG. Advances in Medical Thoracoscopy, 100 years since Jacobaeus. *Respiration* 2010;79:177-86.
34. Lee P, Mathur PN. Editorial: Safe to Sedate for Bronchoscopy despite Respiratory Failure. *Respiration* 2010; 2010;79:276.
35. Lee P, Li S, Lim CK, Aw SE, Colt HG. Selective Apoptosis of Lung Cancer Cells with Talc. *Eur Respir J* 2010;35:450-2.
36. Lee P, Kupeli E, Mehta AC. Airway Stents. *Clin Chest Med* 2010;31:141-50.
37. Phua GC, Rhee KJ, Koh M, Loo CM, Lee P. A Strategy to Improve the Yield of Transbronchial Needle Aspiration. *Surgical Endoscopy* 2010; 24:2105-9.
38. Lee P, Colt HG. Bronchoscopy for Lung Cancer: Appraisal of Current Technology and for the Future. *J Thorac Oncol* 2010;5:1290-300.
39. Lee P. Lung Cancer: Recent Advances. *Ann Acad Med Singapore* 2010;39:819-3.
40. Chan A, Tan KL, Takano A, Lee P. A Middle-aged Asthmatic with Unresolving Cough. *Chest* 2011;139:712-6.
41. See KC, Lee P. Advances in the diagnosis of pleural disease in lung cancer. *Ther Adv Respir Dis.* 2011;5:409-18
42. Wahidi MM, Jain P, Jantz M, Lee P, Mackensen GB, Barbour SY, Lamb C, Silvestri GA. American college of chest physicians consensus statement on the use of topical anesthesia, analgesia, and sedation during flexible bronchoscopy in adult patients. *Chest* 2011;140:1342-50.
43. Loddenkemper R, Mathur PN, Lee P, Noppen M. History and clinical use of thoracoscopy/ pleuroscopy in respiratory medicine. *BREATHE* 2011;8:145-55.
44. Loddenkemper R, Lee P, Noppen M, Mathur PN. Medical thoracoscopy/ pleuroscopy: step by step. *BREATHE* 2011;8:157-67.

45. Lee P. Point: Thoracoscopic Talc Pleurodesis Is the First Choice Management for Malignant Pleural Effusion? Yes. *Chest* 2012;142:15-17.
46. Lee P, Khoo KL. Review of Current Bronchoscopic Interventions for Obstructive Airway Diseases. *Ther Adv Respir Dis.* 2012;6:297-307.
47. Lee P, Colt HG. Pleuroscopy in 2013. *Clin Chest Med.* 2013;34:81-91.
48. Lee P. First primary spontaneous pneumothorax: To pleurodesis or not? Commentary in *Lancet.* *Lancet.* 2013 Apr 13;381(9874):1252-4
49. Simoff MJ, Lally B, Slade MG, Goldberg W, Lee P, Michaud G, Waihide M, Chawla M. Symptom Management in Patients with Lung Cancer: Diagnosis and Management of Lung Cancer, 3rd ed: American College of Chest Physicians Evidence-Based Clinical Practice Guidelines. *Chest.* 2013;143(5 Suppl):e455-97S.
50. Van Boerdonk RA, Brokx HAP, Lee P, Kooi C, Postmus PE et al. Can quantifying free-circulating DNA in plasma be used to identify subjects with high-grade pre-invasive endobronchial lesions? *Oncol Lett.* 2013;5:1591-4.
51. Khoo KL, Mehta AC, Lee P. Endobronchial epinephrine: confusion is in the air. *AJRCCM* 2013;187:1137-8.
52. Kupeli E, Khemasuwan D, Lee P, Mehta AC. Pills and the air passages. *Chest* 2013;144:651-60.
53. Lim CY, Takano A, Yang S, Lee P. Ayurvedic Medicine and Pneumonitis. *Respiration* 2014, Feb 18.
54. Lee P, Eberhardt R, Herth F. Videobronchoscopy for bronchial pre-neoplasia and early central airway cancer: A prospective randomized study (submitted *Lung Cancer*).

BOOK AND BOOK CHAPTERS

1. Lee P, Minai OA, Mehta AC and Ahmad M. Solitary Pulmonary Nodule. *Bone's Atlas of Pulmonary and Critical Care Medicine*, 2nd edition (Campbell GD, Payne DK, eds) 2001; 9:117-125.
2. Lee P, Kupeli E, Mehta AC. Therapeutic Bronchoscopy in Lung Cancer: Laser Therapy, Electrocautery Brachytherapy, Stents and Photodynamic Therapy. *Clinics in Chest Medicine* 2002; 23:241-256.
3. Lee P, Mehta AC. Flexible Bronchoscopy Training. *Flexible Bronchoscopy* 2nd edition (Wang KP, Mehta AC, Turner JF, eds) In: Blackwell Science 2004; 45-50.
4. Lee P, Mehta AC. Therapeutic Flexible Bronchoscopy: An Overview. *Interventional Pulmonary Medicine, Lung Biology in Health and Disease* (Beamis, Mehta and Mathur, eds). In: Marcel and Dekker 2004; 49-87.

5. Lee P, Colt HG. Flex-Rigid Pleuroscopy, Step-by-Step (Lee, Colt, editors). In *CMP Medica Asia* 2005.
6. Lee P. Medical Thoracoscopy. *Oxford Handbook of Clinical Medicine* 2009.
7. Lee P, Beamis J. Competing Technologies: Ultrasound, Navigational Bronchoscopy, OCT: who will win out? (Beamis, Bolliger, Herth, Mayo and Miyazawa editors). In *Progress in Respiratory Research, volume 37: Clinical Chest Ultrasound from the ICU to the Bronchoscopy Suite* 2010
8. Lee P, Kupeli E, Mehta AC. Airway Stents. *Interventional Pulmonary Medicine, Lung Biology in Health and Disease* (Beamis, Mehta and Mathur, eds). In: Marcel and Dekker 2010
9. Lee P, Kupeli E, Mehta AC. Airway Stents. *Clin Chest Med* 2010;31:141-150.
10. Loddenkemper R, Mathur PN, Noppen M, Lee P. *Atlas and Manual of Medical Thoracoscopy/ Pleuroscopy* (Loddenkemper, Mathur, Noppen, Lee, editors). *British Medical Association Award for Best Book for Internal Medicine* 2011.
11. Lee P. Autofluorescence Bronchoscopy and Narrow Band Imaging. *Principles and Practice of Interventional Pulmonology*. Herth and Ernst (editors) 2013.
12. Lee P, Mehta AC. Airway Stents. *Interventional Bronchoscopy: A Clinical Guide* (Prasoon Jain, Atul C Mehta editors). In press.
13. Lee P, Colt HG. Pleuroscopy in 2013. *Clin Chest Med* 2013;34:81-91.
14. Lee P, Astoul P. Medical Thoracoscopy. *Textbook in Pleural Disease*. Light and Lee (editors).
15. Lee P. Endobronchial Tuberculosis. In Jain, Gildea, Metha (editors).