

# VU Research Portal

## **Prenatal screening in twin pregnancies**

Linskens, I.H.

2011

### **document version**

Publisher's PDF, also known as Version of record

[Link to publication in VU Research Portal](#)

### **citation for published version (APA)**

Linskens, I. H. (2011). *Prenatal screening in twin pregnancies*. [PhD-Thesis - Research and graduation internal, Vrije Universiteit Amsterdam].

### **General rights**

Copyright and moral rights for the publications made accessible in the public portal are retained by the authors and/or other copyright owners and it is a condition of accessing publications that users recognise and abide by the legal requirements associated with these rights.

- Users may download and print one copy of any publication from the public portal for the purpose of private study or research.
- You may not further distribute the material or use it for any profit-making activity or commercial gain
- You may freely distribute the URL identifying the publication in the public portal

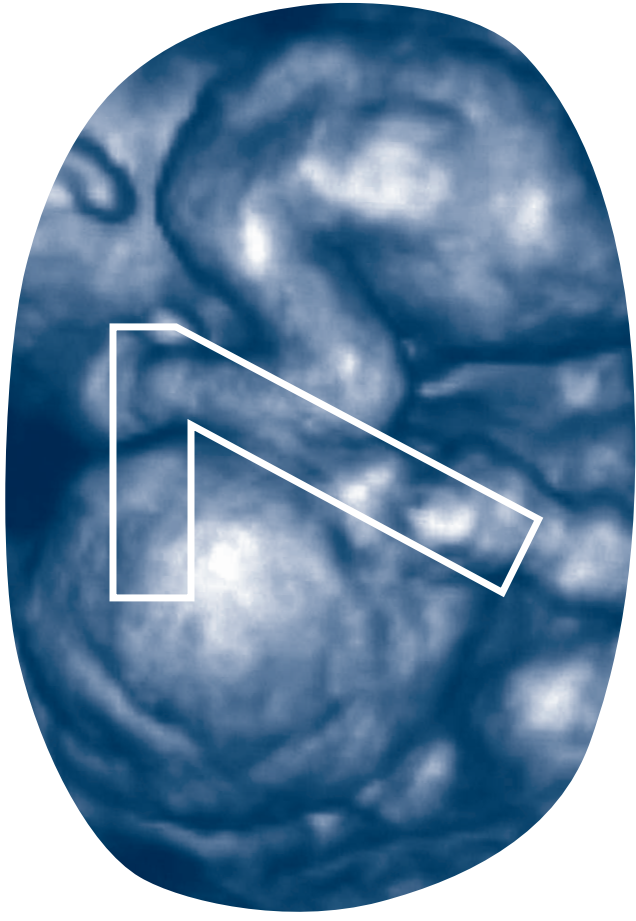
### **Take down policy**

If you believe that this document breaches copyright please contact us providing details, and we will remove access to the work immediately and investigate your claim.

### **E-mail address:**

[vuresearchportal.ub@vu.nl](mailto:vuresearchportal.ub@vu.nl)

- 22** Linskens IH, Spreuwenberg MD, Blankenstein MA, Van Vugt JM. Early first-trimester free beta-hCG and PAPP-A serum distributions in monochorionic and dichorionic twins. *Prenat Diagn* 2009 Jan;29(1):74-8.
- 23** Laigaard J, Pedersen NG, Larsen SO, Hedley PL, Wøjdemann K, Gjerris AC, et al. ADAM12 in first trimester maternal serum from pregnancies conceived by assisted reproduction techniques (ART). *Prenat Diagn* 2009 Jun;29(6):628-9.
- 24** Poon LC, Chelemen T, Minekawa R, Frisova V, Nicolalides KH. Maternal serum ADAM12 (A disintegrin and metalloprotease) in chromosomally abnormal pregnancy at 11-13 weeks. *Am J Obstet Gynecol* 2009 May;200(5):508-6.
- 25** Poon LC, Chelemen T, Granvillano O, Pandeva I, Nicolalides KH. First-trimester maternal serum a disintegrin and metalloprotease 12 (ADAM12) and adverse pregnancy outcome. *Obstet Gynecol* 2008 Nov;112(5):1082-90.
- 26** Pihl K, Larsen T, Krebs L, Christiansen M. First trimester maternal serum PAPP-A, beta-hCG and ADAM12 in prediction of small-for-gestational-age fetuses. *Prenat Diagn* 2008 Dec;28(12):1131-5.



I.H. Linskens – Y.M. de Mooij – J.W.R. Twisk – W.J. Kist – D. Oepkes – J.M.G. van Vugt

.....

**Discordance in nuchal translucency measurements in monochorionic diamniotic twins as predictor of Twin-to-Twin Transfusion syndrome**

.....

*Twin Res Hum Genet.* 2009 Dec;12(6):605-10

## Abstract

### • • • Objective

Discordance in nuchal translucency measurements in monochorionic diamniotic twin pregnancies was assessed as predictor of Twin-to-Twin Transfusion syndrome (TTTS).

### • • • Study Design

A total of 61 monochorionic diamniotic twins were enrolled. Nuchal translucency (NT) and crown-rump-length (CRL) discordance was calculated as the percentage of delta NT and CRL (absolute difference NT/CRL fetus 1 and fetus 2) of the largest measurement, and correlated with subsequent development of TTTS.

### • • • Results

TTTS developed in 14/61 (23%) of cases. A NT discordance of 20% or more best predicted TTTS development, with a sensitivity of 64% and a specificity of 78%. We found a positive predictive value of 50% and negative predicted value of 86% for TTTS development if NT discordance was 20% or more.

### • • • Conclusion

NT discordance of more than 20% in monochorionic diamniotic twins is associated with an increased risk for subsequent development of TTTS and earlier presentation of symptoms.

## Introduction

Twin-to-Twin Transfusion syndrome (TTTS) occurs in approximately 15% of all monochorionic twin pregnancies<sup>1,2</sup>. The syndrome is defined ultrasonographically by the presence of a polyhydramnios in the sac of one twin and oligohydramnios in the sac of the other twin. Without intervention, TTTS often leads to either severe morbidity, mostly associated with preterm birth, or demise of one or both fetuses<sup>3</sup>. Timely diagnosis of TTTS is beneficial for treatment options and outcome<sup>4-6</sup>.

Fetal nuchal translucency (NT) measurement is an ultrasound measurement in which the thickness of a fluid collection in the neck of the fetus is measured. NT measurements are commonly used as fetal marker for aneuploidy screening between 11 and 14 weeks of gestation. An increased NT is also associated with a variety of fetal structural abnormalities, mainly cardiac defects and genetic syndromes<sup>7-9</sup>. In monochorionic diamniotic twins, an association between an increased NT in one fetus with later development of TTTS has been suggested<sup>10,11</sup>. The aim of the current study was to assess the value of discordance in NT measurements in monochorionic diamniotic twins to predict TTTS.

## Materials and Methods

Data of all monochorionic diamniotic twin pregnancies were extracted from the fetal database of a tertiary fetal medicine referral center, the VU university medical center Amsterdam (VUMC), between 2004 and 2008. Data of twins that had been referred to the VUMC for prenatal Down syndrome screening in the first trimester with nuchal translucency measurements and who had serial follow up ultrasonography were analyzed. All twins had an early first trimester ultrasound during which the chorionicity was determined and crown rump length (CRL) and NT were measured according to standards defined by the Fetal Medicine Foundation<sup>12</sup>. Risk assessment for trisomy 21 was calculated using maternal age and individual NT measurements of both fetuses. Parents with a screen positive test result (cut-off 1:200) were counseled concerning the risk for trisomy 21 and the risk of invasive testing and then opted for, or refrained from invasive testing.

All women had serial follow up ultrasonography, including a detailed anomaly scan including echocardiography at 18 to 20 weeks' gestation. If TTTS was suspected, patients were referred to the Leiden University Medical Center, the national center for invasive fetal therapy in the Netherlands. TTTS was classified according to Quintero stages<sup>2</sup>. Pregnancy outcome was evaluated by questionnaires and delivery room records.

### • • • Statistical analysis

Patient characteristics of all twins are presented as median values (range) and percentages. Differences between the groups (uncomplicated versus TTTS) were tested for significance with chi-square tests and Mann-Whitney U test. NT and CRL discordance was calculated

as the percentage of delta NT and CRL (absolute difference NT/CRL fetus 1 and fetus 2) of the largest measurement in accordance to the study of Kagan et al.<sup>11</sup> To investigate whether NT discordance can predict the development of TTTS, sensitivity and specificity were calculated at different cut-offs in NT discordance to construct a receiver operating characteristics (ROC) curve. Subsequently, the area under the curve was calculated. A prediction model for TTTS was constructed using logistic regression analysis. Statistical analyses were performed using SPSS version 15.0 (Chicago, IL, USA). P-values <0.05 were considered significant.

## Results

A total of 61 monozygotic diamniotic twin pregnancies were included. Data on first trimester nuchal translucency measurements, serial follow-up ultrasonography and fetal outcome were known. Apart from two cases, in which a single umbilical artery was found, none of the fetuses showed structural anomalies. Either invasive diagnostics demonstrated a normal karyotype or in case a karyotyping was not done healthy neonates were born without dysmorphic features and thus considered to have normal karyotype. TTTS developed in 14/61 (23%) of the pregnancies. In three cases fetal demise of one or both

**Table 1** Characteristics of the 41 uncomplicated monozygotic twin pregnancies and 14 pregnancies with TTTS

	Uncomplicated n 41	TTTS n 14	p-value * < 0.05
Median maternal age in years (range)	34.4 (21-41)	31.8 (20-41)	0.34
Ethnicity (%)			
-Caucasian	95	93	0.75
-Non-Caucasian	5	7	
Smoking (%)			
-no	90	93	0.77
-yes	10	7	
Parity (%)			
-nullipara	49	50	0.94
-multipara	51	50	
Conception			
-naturally conceived	95	86	0.24
-assisted reproduction (IVF/ICSI)	5	14	
Median CRL discordance	3% (0-19%)	6% (0-23%)	0.22
Median NT discordance	9% (0-36%)	28% (0-91%)	0.019*
Median gestational age at delivery	36+1 (28+1-39+1)	30+6 (17+3-40+2)	0.013*

**Table 2** TTTS case descriptions

**Note** Nine of the fourteen TTTS cases had more than 20% NT discordance. Survival of both fetuses was 5/14 (36%) and of at least one fetus 10/14 (71%)

	CRL 1 (mm)	NT 1 (mm)	CRL 2 (mm)	NT 2 (mm)	NT discordance ≥ 20%	Quintero stage	Therapy	Survival (n) and GA at birth
I	63	9.3	74	2.1	Yes	III	UCC 15+6 D	1, 41 wks
II	62	0.9	48	9.6	Yes	III	UCC 17+0 D	0, 18 wks
III	65	1.2	68	4.0	Yes	III	NO 16+2	TOP, 18 wks
IV	57	1.2	70	2.1	Yes	III	Laser 14+3	1, 40 wks
V	75	1.1	76	1.8	Yes	III	Laser 17+5	2, 30 wks
VI	69	1.6	71	1.2	Yes	II	Laser 20+1	2, 34 wks
VII	53	1.6	59	1.1	Yes	III	Laser 19+3	0, 23 wks
VIII	59	1.6	59	1.1	Yes	III	Laser 19+2	2, 30 wks
IX	62	1.0	57	1.3	Yes	III	Laser 23+5	2, 37 wks
X	61	1.5	57	1.4	No	II	Laser 22+5	1, 32 wks
XI	58	2.0	63	2.0	No	III	AR 22+1	1, 38 wks
XII	55	1.1	54	1.1	No	III	Laser 20+3	0, 26 wks
XIII	67	1.3	68	1.2	No	III	Laser 20+0	1, 33 wks
XIV	62	1.5	59	1.7	No	III	Laser 24+2	2, 30 wks

**UCC** – umbilical cord coagulation; **NO** – no therapy; **AR** – amnioreduction; **D** – donor fetus; **GA** – gestational age; **TOP** – termination of pregnancy

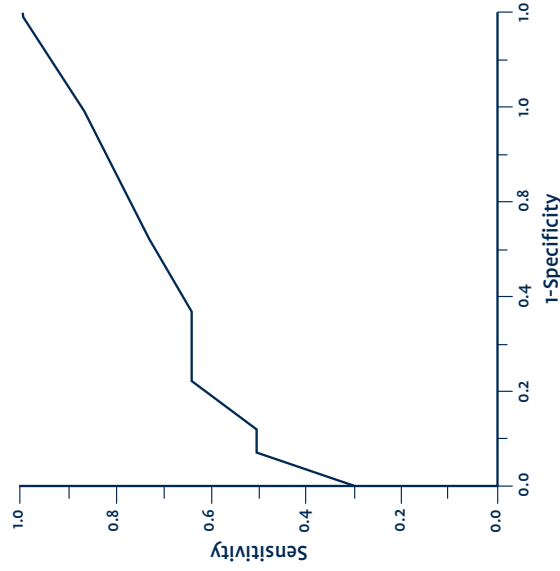
fetuses occurred, and three twins were born immaturely. However, in these six cases no ultrasound signs of TTTS were present and were therefore excluded from further analysis. Outcome was uncomplicated (defined as birth after 26 weeks of gestation, no TTTS or fetal demise) in 41 pregnancies (41/61 = 67%). Table 1 summarizes the characteristics of the uncomplicated and TTTS pregnancies for maternal age, ethnicity, smoking, parity, conception, median CRL/NT discordance and gestational age at birth. Detailed TTTS case descriptions are present in Table 2. CRL at the time of NT measurement ranged from 48-79 mm, median 62 mm and NT ranged from 0.7-9.6 mm, median 1.3 mm. An increased NT (> 3.5 mm) was seen in three fetuses of the TTTS group and none in the uncomplicated group.

To evaluate the best cut-off level for NT discordance, sensitivity and specificity were calculated at different cut-off levels, and a receiver operating characteristics (ROC) curve was constructed (Table 3 and Figure 1). The area under the ROC curve was 0.71. NT

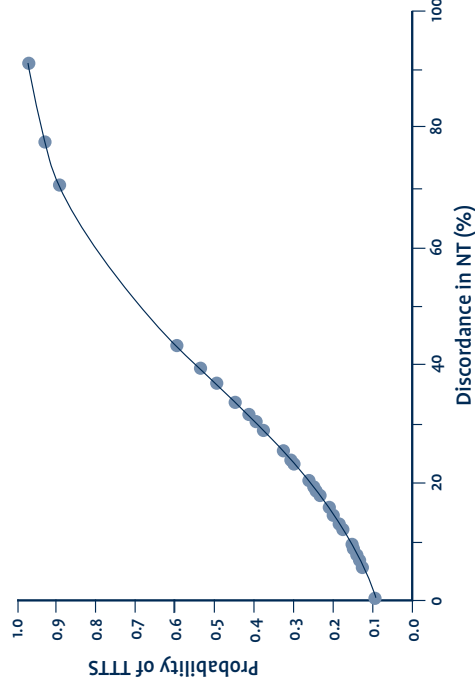
**Table 3** Sensitivity and specificity calculated from different cut-off levels of percentage of discordance in nuchal translucency discordance

NT discordance % cut-off level	Sensitivity	Specificity
5%	86%	22%
10%	71%	51%
15%	64%	63%
20%	64%	78%
25%	50%	88%
30%	50%	93%
40%	29%	100%
50%	21%	100%
60%	21%	100%
70%	14%	100%
80%	7%	100%
90%	7%	100%
100%	0%	100%

**Figure 1** Receiver operating characteristics (ROC) curve: relationship between sensitivity and specificity in the prediction of TTTS by discordance in fetal nuchal translucency measurements



**Figure 2** Probability of TTTS at different cut-off levels of discordance in nuchal translucency measurements (%)



discordance of 20% or more demonstrated a sensitivity of 64% (9/14) and specificity of 78% (32/41) for the subsequent development of TTTS, with a positive predictive value of 50% (9/18) and negative predictive value of 86% (32/37). NT discordance of 20% or more was more frequently observed in the TTTS cases (9/14= 64%) compared with the uncomplicated group (9/41=22%) (Chi-Square,  $p= 0.004$ ).

Logistic regression analysis demonstrated that NT discordance (%) was independently associated with subsequent development of TTTS ( $p=0.008$ ), no quadratic relation was found. For CRL discordance (%) and subsequent development of TTTS the association was not significant ( $p=0.09$ ). As a result of the logistic regression analysis, the probability of TTTS development for a certain percentage of NT discordance was calculated (Figure 2). If the NT's of the two fetuses are similar the risk for development of TTTS was 8.9%. The probability of TTTS development increased gradually with increasing NT discordance. If NT discordance 20% or more was used as a categorical variable (yes/no) logistic regression analysis demonstrated a significant association with TTTS development,  $p=0.006$ , OR 6.4 (95% CI: 1.7-23.9).

## Discussion

Our study confirms a previously suggested association between NT discordance in monozygotic twins with subsequent development of TTTS<sup>1,10,11</sup>. We found the optimal cut-off for NT discordance to be 20% or more. The current research shows that a larger NT discordance is associated with higher chance of TTTS development. In the group with 20%

or more NT discordance, the risk for later chance of development of TTTS was more than 5 times higher (50% versus 9%) than in twins with identical measurement of the NT. The use of NT measurements is general practice in screening for trisomies 7. Finding discordance in fetal NT in monozygotic twins is a challenge for the counsellor. Several cases have been described of monozygotic twin pairs concordant for a chromosomal abnormality but with dissimilar NT values 13:14. In addition, although monozygotic twins are considered genetically 'identical' a small number of discordances for chromosomal abnormalities has been described 15:16. To account for heterozygotic twinning, individual fetal karyotyping should be considered in monozygotic twins with dissimilar NT values. Amniocentesis with individual aspiration of each fetal sac may provide more reliable test results compared with chorionic villus sampling 17:18. Postponing invasive diagnostics to a more advanced gestation age might be beneficial since structural fetal abnormalities can be more easily visualized and signs of TTTS can become present in the mean time.

Fetal structural abnormalities are more frequently seen in monozygotic twins compared with singletons and discordance in structural abnormalities has been described 19. Since increased NT is also associated with structural fetal abnormalities, mostly cardiac abnormalities, targeted structural ultrasonography with echocardiography is indicated 89. Increased NT measurements are more frequently seen in chromosomally normal monozygotic twin pregnancies in comparison with dichorionic twins and singletons 20. The earliest reports on the association between increased NT (defined as NT>95th centile) and early TTTS described a positive predictive value of 38% and negative predictive value of 91% 10. In monozygotic twin fetuses with increased NT (defined as NT>95th centile) a more than three-fold increase in risk for TTTS development was described 1. However, a study by El Kateb et al. found no significant association between increased NT (defined as NT>95th centile) and TTTS development, but only a tendency for TTTS development in those cases with increased NT, namely 20% versus 4% in those with NT < 95th centile 21. Recently Kagan et al. found in a large series monozygotic twins a detection rate of 52% for TTTS and 63% for early fetal death using NT discordance as parameter with a cut-off of 20% or more. If NT discordance was less than 20% the risk of complications was less than 10% 1. Sperleng et al. found no relationship between NT discordance and subsequent TTTS development; however, they studied only the absolute NT difference of 0.5 mm between both fetuses and not NT discordance as percentage of delta NT of the largest measurement 22. An interesting and new finding in our study was that in TTTS cases with NT discordance less than 20% (Table 2, Case X-XIV) fetuses generally presented with TTTS symptoms after 20 weeks of gestation. This is in contrast to the group with NT discordance of 20% or more in which the earliest case was diagnosed at 14+3 wks and median gestational age at diagnosis was 17+5 wks.

Monozygotic twin pregnancies are characterized by the presence of vascular anastomoses between the two fetoplacental circulations 23. Sebire et al. (2000) hypothesized that in monozygotic twins, the mechanism for increased NT as an early manifestation of TTTS is likely to be cardiac dysfunction due to hypervolaemic congestion in the recipient twin 1. The placental vascular pattern is thought to be dynamic in the first trimester, with 'asymmetric reduction in placental anastomoses'. According to this hypothesis in early pregnancy all monozygotic twins have a large number of bidirectional

arteriovenous connections, but with advancing gestation there is progressive spontaneous closure of disruption of these anastomoses 11:24. This hypothesis is in accordance with the findings of our study, as not all monozygotic twins with NT discordance of more than 20% developed TTTS. We observed two pregnancies with development of TTTS in which the subsequent donor fetus presented an extreme enlarged NT and smaller CRL. Although in literature the increased NT is assigned to the recipient fetus due to the placental dynamics in the first trimester, this phenomenon, increased NT in the smaller donor fetus, could also be seen as support for the asymmetric reduction theory. Possibly, Kagan et al. already described this phenomenon, since only 27 of the 33 of their TTTS represented a higher NT in the fetus with higher CRL. However, information concerning identification of recipient/donor fetus was lacking 1.

From our results, although a relatively small number of twins has been studied, it may be concluded that NT discordance of more than 20% in monozygotic twin pregnancies should raise a high level of suspicion for subsequent development of TTTS. Intensive ultrasound follow-up or even referral to a specialized clinic is advisable. Biweekly ultrasound examinations combined with detailed patient instructions for rapidly increasing abdominal girth or premature contractions can aid in the timely diagnosis of TTTS and is a safe monitoring program for monozygotic twins 25. Fetal outcome benefits from early and timely TTTS diagnosis and treatment 4:6. In the future, standardized NT measurements might be considered for all monozygotic twins as TTTS screening tool besides aneuploidy screening. Larger prospective studies on monozygotic twins including NT and hemodynamic profiles are necessary to evaluate the benefit for TTTS screening.

## References

- 1) Sebire NJ, Souka A, Skentou H, Geerts L, Nicolaides KH. Early prediction of severe twin-to-twin transfusion syndrome. *Hum Reprod* 2000 Sep;15(9):2008-10.
- 2) Quintero RA, Morales WJ, Allen MH, Bornick PW, Johnson PK, Kruger M. Staging of twin-twin transfusion syndrome. *J Perinatol* 1999 Dec;19(8 Pt 1):550-5.
- 3) Berghella V, Kaufmann M. Natural history of twin-twin transfusion syndrome. *J Reprod Med* 2001 May; 46(5):480-4.
- 4) Middeldorp JM, Sueters M, Lopriore E, Klumper FJ, Oepkes D, Devlieger R, et al. Fetoscopic laser surgery in 100 pregnancies with severe twin-to-twin transfusion syndrome in the Netherlands. *Fetal Diagn Ther* 2007;22(3):190-4.
- 5) Senat MV, Deprest J, Boulvain M, Paupe A, Winer N, Ville Y. Endoscopic laser surgery versus serial amnioreduction for severe twin-to-twin transfusion syndrome. *N Engl J Med* 2004 Jul 8;351(2):136-44.
- 6) Huber A, Diehl W, Bregenzler T, Hackelner BJ, Hecher K. Stage-related outcome in twin-twin transfusion syndrome treated by fetoscopic laser coagulation. *Obstet Gynecol* 2006 Aug;108(2):333-7.
- 7) Nicolaides KH, Azar G, Byrne D, Mansur C, Marks K. Fetal nuchal translucency: ultrasound screening for chromosomal defects in first trimester of pregnancy. *BMJ* 1992 Apr 4;304(6831):867-9.
- 8) Souka AP, Von Kaisenberg CS, Hyett JA, Sonek JD, Nicolaides KH. Increased nuchal translucency with normal karyotype. *Am J Obstet Gynecol* 2005 Apr;192(4):1005-21.
- 9) Hyett JA, Perdu M, Sharland GK, Snijders RS, Nicolaides KH. Increased nuchal translucency at 10-14 weeks of gestation as a marker for major cardiac defects. *Ultrasound Obstet Gynecol* 1997 Oct;10(4):242-6.
- 10) Sebire NJ, D'Ercole C, Hughes K, Carvalho M, Nicolaides KH. Increased nuchal translucency thickness at 10-14 weeks of gestation as a predictor of severe twin-to-twin transfusion syndrome. *Ultrasound Obstet Gynecol* 1997 Aug;10(2):86-9.
- 11) Kagan KO, Gazzoni A, Sepulveda-Gonzalez G, Sotiriadis A, Nicolaides KH. Discordance in nuchal translucency thickness in the prediction of severe twin-to-twin transfusion syndrome. *Ultrasound Obstet Gynecol* 2007 May;29(5):327-32.
- 12) Sepulveda W, Sebire NJ, Hughes K, Odibo A, Nicolaides KH. The lambda sign at 10-14 weeks of gestation as a predictor of chorionicity in twin pregnancies. *Ultrasound Obstet Gynecol* 1996 Jun;7(6):421-3.
- 13) Pandya PP, Hilbert F, Snijders RJ, Nicolaides KH. Nuchal translucency thickness and crown-rump length in twin pregnancies with chromosomally abnormal fetuses. *J Ultrasound Med* 1995 Aug;14(8):565-8.
- 14) Vandercruys H, Falola S, Auer M, Sebire N, Nicolaides KH. Screening for trisomy 21 in monozygotic twins by measurement of fetal nuchal translucency thickness. *Ultrasound Obstet Gynecol* 2005 Jun;25(6):551-3.
- 15) Nieuwint A, Van Zalen-Sprock R, Hummel P, Pals G, Van Yugt J, Van Der Harten H, et al. 'Identical' twins with discordant karyotypes. *Prenat Diagn* 1999 Jan;19(1):72-6.
- 16) Gilbert B, Yardin C, Briault S, Belin V, Lienhardt A, Aubard Y, et al. Prenatal diagnosis of female monozygotic twins discordant for Turner syndrome: implications for prenatal genetic counselling. *Prenat Diagn* 2002 Aug;22(8):697-702.
- 17) Chen CP, Chang TY, Chern SR, Town DD, Pan CW, Lee MS, et al. Early second-trimester diagnosis of monozygotic twins discordant for cystic hygroma coli and Turner syndrome. *Prenat Diagn* 2003 Apr;23(4):352-3.
- 18) Gentilin B, Gueneri S, Bianchi V, Natacci F, Colombo A, Fogliani R, et al. Discordant prenatal phenotype and karyotype of monozygotic twins characterized by the unequal distribution of two cell lines investigated by different methods: a review. *Twin Res Hum Genet* 2008 Jun;11(3):352-6.
- 19) Hall JG. Twinning. *Lancet* 2003 Aug 30;362(9385):735-43.
- 20) Sebire NJ, Snijders RJ, Hughes K, Sepulveda W, Nicolaides KH. Screening for trisomy 21 in twin pregnancies by maternal age and fetal nuchal translucency thickness at 10-14 weeks of gestation. *Br J Obstet Gynaecol* 1996 Oct;103(10):999-1003.
- 21) El Kateb A, Nasr B, Nassar M, Bernard JP, Ville Y. First-trimester ultrasound examination and the outcome of monozygotic twin pregnancies. *Prenat Diagn* 2007 Oct;27(10):922-5.
- 22) Sperling L, Kill C, Larsen LU, Brocks V, Wojdemann KR, Qvist J, et al. Detection of chromosomal abnormalities, congenital abnormalities and transfusion syndrome in twins. *Ultrasound Obstet Gynecol* 2007 May;29(5):517-26.

- 23) Robertson EG, Neer KJ. Placental injection studies in twin gestation. *Am J Obstet Gynecol* 1983 Sep 15; 147(2):170-4.
- 24) Sebire NJ, Talbert D, Fisk NM. Twin-to-twin transfusion syndrome results from dynamic asymmetrical reduction in placental anastomoses: a hypothesis. *Placenta* 2001 May;22(5):383-91.
- 25) Sueters M, Middeldorp JM, Lopriore E, Oepkes D, Kanhai HH, Vandenbussche FP. Timely diagnosis of twin-to-twin transfusion syndrome in monozygotic twin pregnancies by biweekly sonography combined with patient instruction to report onset of symptoms. *Ultrasound Obstet Gynecol* 2006 Oct;28(5):659-64.