

VU Research Portal

Prenatal screening in twin pregnancies

Linskens, I.H.

2011

document version

Publisher's PDF, also known as Version of record

[Link to publication in VU Research Portal](#)

citation for published version (APA)

Linskens, I. H. (2011). *Prenatal screening in twin pregnancies*. [PhD-Thesis - Research and graduation internal, Vrije Universiteit Amsterdam].

General rights

Copyright and moral rights for the publications made accessible in the public portal are retained by the authors and/or other copyright owners and it is a condition of accessing publications that users recognise and abide by the legal requirements associated with these rights.

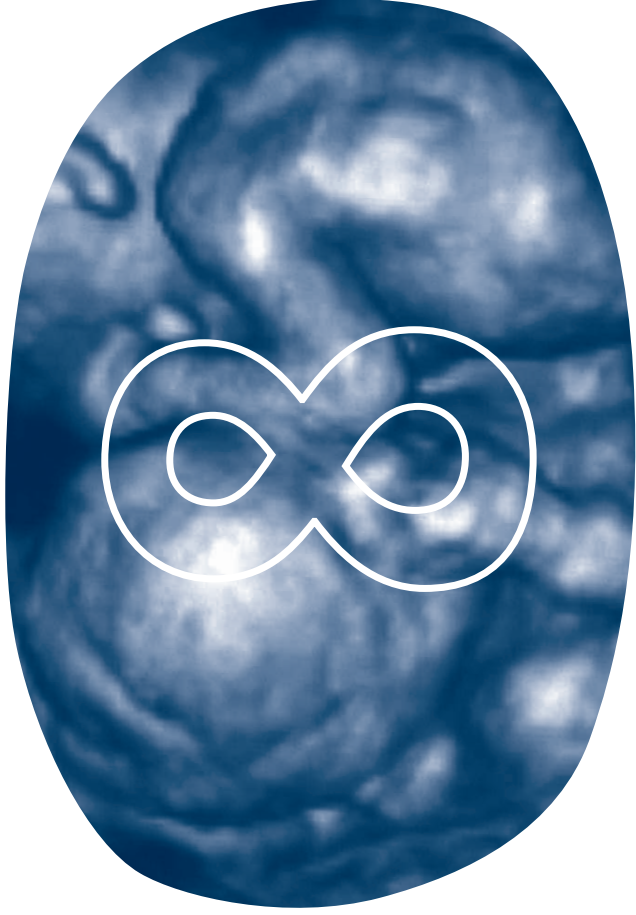
- Users may download and print one copy of any publication from the public portal for the purpose of private study or research.
- You may not further distribute the material or use it for any profit-making activity or commercial gain
- You may freely distribute the URL identifying the publication in the public portal

Take down policy

If you believe that this document breaches copyright please contact us providing details, and we will remove access to the work immediately and investigate your claim.

E-mail address:

vuresearchportal.ub@vu.nl



I.H. Linskens – M.A.J. Engels – D. Oepkes – A.C. Heijboer – M.A. Blankenstein – J.M.G. van Vugt

.....

A trend towards increased first trimester

free-hCG and PAPP-A in monochorionic twins

complicated by Twin-to-Twin

Transfusion syndrome

.....

Prenat Diagn. 2010 Sep;30(9):909-10

Research letter

First trimester combined screening calculates the individual risk for a woman carrying a pregnancy affected by Down syndrome (DS) from the ultrasound measurement of the nuchal translucency (NT), maternal serum free β human Chorionic Gonadotrophin (free β -hCG) combined with pregnancy associated plasma protein-A (PAPP-A) and background risk based on maternal age. First trimester biochemical DS screening markers have been described in relation to adverse pregnancy outcome such as preeclampsia, fetal growth restriction, stillbirth and preterm birth in singleton pregnancies¹. Approximately 9% to 15% of all monochorionic (MC) twin pregnancies have been described to be complicated by Twin-to-Twin Transfusion syndrome (TTTS)^{2,3}. TTTS without intervention leads to either severe morbidity, mostly associated with preterm birth, or demise of one or both fetuses^{3,4}.

The association between NT discordance \geq 20% between fetuses in MC twins and subsequent development of TTTS was described earlier^{5,6}. Biochemical markers for the identification of MC pregnancies at risk for TTTS would be highly useful in clinical practice for early and timely diagnosis and subsequent therapy of TTTS, besides the use of NT discordance. Second trimester DS serum markers were recently suggested to be increased in MC twin pregnancies complicated by TTTS^{7,8}. In sixty TTTS cases, the median multiple of the median (MoM) second trimester free β -hCG (corrected for twin chorionicity) was significantly increased (1.39 vs 0.98) compared with MC twins with uncomplicated outcome. For alpha-fetoprotein (AFP) there was a small increase of 1.15 versus 0.99 in TTTS compared with uncomplicated MC twin pregnancies, but not significant^{7,9}.

In the current study we tested the hypothesis that first trimester biochemical markers used for DS screening are discriminative and possibly predictive for TTTS. If so, first trimester assessment might be preferable to second trimester measurement. Cases of MC twins referred for first trimester DS screening were extracted from the fetal database of our tertiary fetal medicine referral center between September 2004 and April 2009. Chorionicity was classified as MC if there was a single placental mass in the absence of the λ -sign at the inter-twin membrane-placental junction¹⁰. Complete data were available from 56 MC twins. PAPP-A and free β -hCG were measured between 9 and 14 weeks of gestation using the DelfiaXpress (PerkinElmer, Turku, Finland). Coefficients of variation (CV) for free β -hCG and PAPP-A in this period were below 4% at all levels. Free β -hCG concentrations ranged from 24 to 282 μ g/L and PAPP-A ranged from 220 to 12700 mU/L. Biochemical markers were expressed as weight-corrected MoM values for unaffected singletons. Pregnancy outcome was evaluated by questionnaires and delivery room records. The mean maternal age was 34.3 years (range 20-41 years). The median gestational age at sampling was 85 days (range 63-96 days). The outcome was uncomplicated in 39 cases and 12 cases were complicated by TTTS. Five cases were complicated by fetal demise of at least one fetus without signs of TTTS. If TTTS was suspected, patients were referred to the Leiden University Medical Center, the national center for invasive fetal therapy in the Netherlands. TTTS was classified according to Quintero stages: in two cases stage II and all others stage III³. In all MC twins (n=56) the median MoM free β -hCG was 1.59 MoM and PAPP-A 1.78 MoM. Table 1 reports

on median free β -hCG and PAPP-A differentiated for pregnancy outcome. There was a trend toward higher free β -hCG median MoM values in the TTTS group (n=12) compared with the uncomplicated group (n=39) (1.99 vs 1.53 MoM), but the difference did not reach statistical significance (Mann-Whitney U; p=0.32). The logtransformed free β -hCG MoM's were also not significantly different (T-test; p=0.51) with SD's 0.51 and 0.58 respectively in the TTTS and uncomplicated group. The median MoM for PAPP-A was slightly but also not significantly higher in the TTTS group (1.94 vs 1.69 MoM, Mann-Whitney U; p=0.51). The log transformed PAPP-A MoM's were not significantly different (T-test; p=0.45) with SD's 0.53 and 0.65 respectively in the TTTS and uncomplicated group. Median MoM's in the TTTS group subdivided for outcome showed increased free β -hCG and PAPP-A in cases with no survivors (n=3) compared with those with at least one surviving fetus (n=9), i.e. 2.16 versus 1.82 for free β -hCG and 2.15 versus 1.85 for PAPP-A. These differences were, however, not statistically significant.

In conclusion, first trimester DS serum markers were found to have a tendency toward increased values in MC twins developing TTTS; however, this increase was not significant compared with uncomplicated pregnancies. The increase in maternal free β -hCG is suggested to reflect changes in placenta, possibly trophoblast damage, due to TTTS. The increase in maternal free β -hCG may reflect changes in placental oxygen tension secondary to uteroplacental hypoperfusion⁸. Because placental damage is limited in early pregnancy this could explain why first trimester serum markers were found somewhat increased but not discriminative. In the Sermondade study samples were taken as part of the routine second trimester screening program for DS, in a setting comparable to ours. However, in the study by Fox and colleagues samples were taken at time of TTTS diagnosis (presuming thus more placental damage) and this may account for the fact that a median free β -hCG MoM of 5.75 (not corrected for twin chorionicity) was more increased compared with the 1.39 found by Sermondade et al. (2009) (7:8). Recently anti-angiogenic factors (soluble endoglin (S-Eng) and soluble vascular endothelial growth factor receptor-1 (VEGFR-1)), were reported to be increased in maternal plasma of TTTS cases (n=16) and the angiogenic factor (placental growth factor (PLGF)) decreased between 16-26 weeks of gestation¹¹.

This is the first report on first trimester free β -hCG and PAPP-A in MC twins complicated by TTTS. In MC twins later developing TTTS, we found a trend toward higher values of first trimester free β -hCG and PAPP-A. Larger studies are needed to confirm our data if assessment of first trimester free β -hCG and PAPP-A will be of diagnostic or prognostic value for individual patients.

• • • Acknowledgment

We thank Prof.dr. J.W.R. Twisk (Department of Clinical Epidemiology and Biostatistics) for his statistical support.

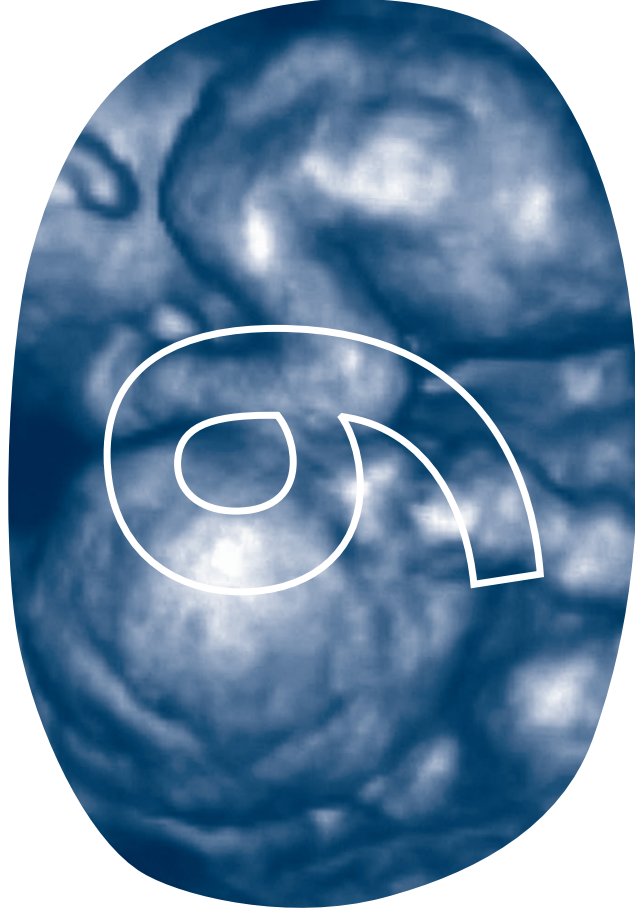
Table 1 Median MoM free β -hCG and PAPP-A in uncomplicated MC twin pregnancies and MC twin pregnancies complicated by TTTS

| | MC uncomplicated (n 39) | MC TTTS (n 12) | p-value |
|------------------------------|-------------------------|----------------|---------|
| Median MoM free β -hCG | 1.53 | 1.99 | 0.32 |
| Median MoM PAPP-A | 1.69 | 1.94 | 0.51 |

MC – monochorionic; **MoM** – Multiple of the Median; **TTTS** – Twin-to-Twin Transfusion syndrome; **hCG** – human Chorionic Gonadotropin; **PAPP-A** – pregnancy associated plasma protein-A

References

- Dugoff L, Hobbins JC, Malone FD, Porter TF, Luthy D, Comstock CH, et al. First-trimester maternal serum PAPP-A and free-beta subunit human chorionic gonadotropin concentrations and nuchal translucency are associated with obstetric complications: a population-based screening study (the FASTER Trial). *Am J Obstet Gynecol* 2004 Oct;191(4):1446-51.
- Lewi L, Jani J, Blickstein I, Huber A, Gucciardo L, Van MT, et al. The outcome of monochorionic diamniotic twin gestations in the era of invasive fetal therapy: a prospective cohort study. *Am J Obstet Gynecol* 2008 Nov;199(5):514-8.
- Quintero RA, Morales WJ, Allen MH, Bornick PW, Johnson PK, Kruger M. Staging of twin-twin transfusion syndrome. *J Perinatol* 1999 Dec;19(8 Pt 1):550-5.
- Berghella V, Kaufmann M. Natural history of twin-twin transfusion syndrome. *J Reprod Med* 2001 May;46(5):480-4.
- Kagan KO, Gazzoni A, Sepulveda-Gonzalez G, Sotiriadis A, Nicolaidis KH. Discordance in nuchal translucency thickness in the prediction of severe twin-to-twin transfusion syndrome. *Ultrasound Obstet Gynecol* 2007 May;29(5):527-32.
- Linskens IH, de Mooij YM, Twisk JW, Kist WJ, Oepkes D, Van Vugt JM. Discordance in nuchal translucency measurements in monochorionic diamniotic twins as predictor of twin-to-twin transfusion syndrome. *Twin Res Hum Genet* 2009 Dec;12(6):605-10.
- Sermondade N, Dreux S, Oury JF, Muller F. Second-trimester maternal serum screening for Down syndrome in twin-to-twin transfusion syndrome. *Prenat Diagn* 2009 Aug;29(8):814-5.
- Fox CE, Pretlove SJ, Chan BC, Mahony RT, Holder R, Kilby MD. Maternal serum markers of placental damage in uncomplicated dichorionic and monochorionic pregnancies in comparison with monochorionic pregnancies complicated by severe twin-to-twin transfusion syndrome and the response to fetoscopic laser ablation. *Eur J Obstet Gynecol Reprod Biol* 2009 Jun;144(2):124-9.
- Muller F, Dreux S, Dupoizat H, Uzan S, Dubin MF, Oury JF, et al. Second-trimester Down syndrome maternal serum screening in twin pregnancies: impact of chorionicity. *Prenat Diagn* 2003 Apr;23(4):331-5.
- Sepulveda W, Sebire NJ, Hughes K, Odibo A, Nicolaidis KH. The lambda sign at 10-14 weeks of gestation as a predictor of chorionicity in twin pregnancies. *Ultrasound Obstet Gynecol* 1996 Jun;7(6):421-3.
- Kusanovic JP, Romero R, Espinoza J, Nien JK, Kim CJ, Mittal P, et al. Twin-to-twin transfusion syndrome: an antiangiogenic state? *Am J Obstet Gynecol* 2008 Apr;198(4):382-8.



I.H. Linskens – R.M. van Elburg – D. Oepkes – J.M.G. van Vugt – M.C. Haak

Expectant management in multiple pregnancies with discordant structural fetal anomalies

Submitted