

# VU Research Portal

## Adolescent idiopathic scoliosis: spinal fusion and beyond

Holewijn, R.M.

2019

### **document version**

Publisher's PDF, also known as Version of record

[Link to publication in VU Research Portal](#)

### **citation for published version (APA)**

Holewijn, R. M. (2019). *Adolescent idiopathic scoliosis: spinal fusion and beyond*. [PhD-Thesis - Research and graduation internal, Vrije Universiteit Amsterdam].

### **General rights**

Copyright and moral rights for the publications made accessible in the public portal are retained by the authors and/or other copyright owners and it is a condition of accessing publications that users recognise and abide by the legal requirements associated with these rights.

- Users may download and print one copy of any publication from the public portal for the purpose of private study or research.
- You may not further distribute the material or use it for any profit-making activity or commercial gain
- You may freely distribute the URL identifying the publication in the public portal

### **Take down policy**

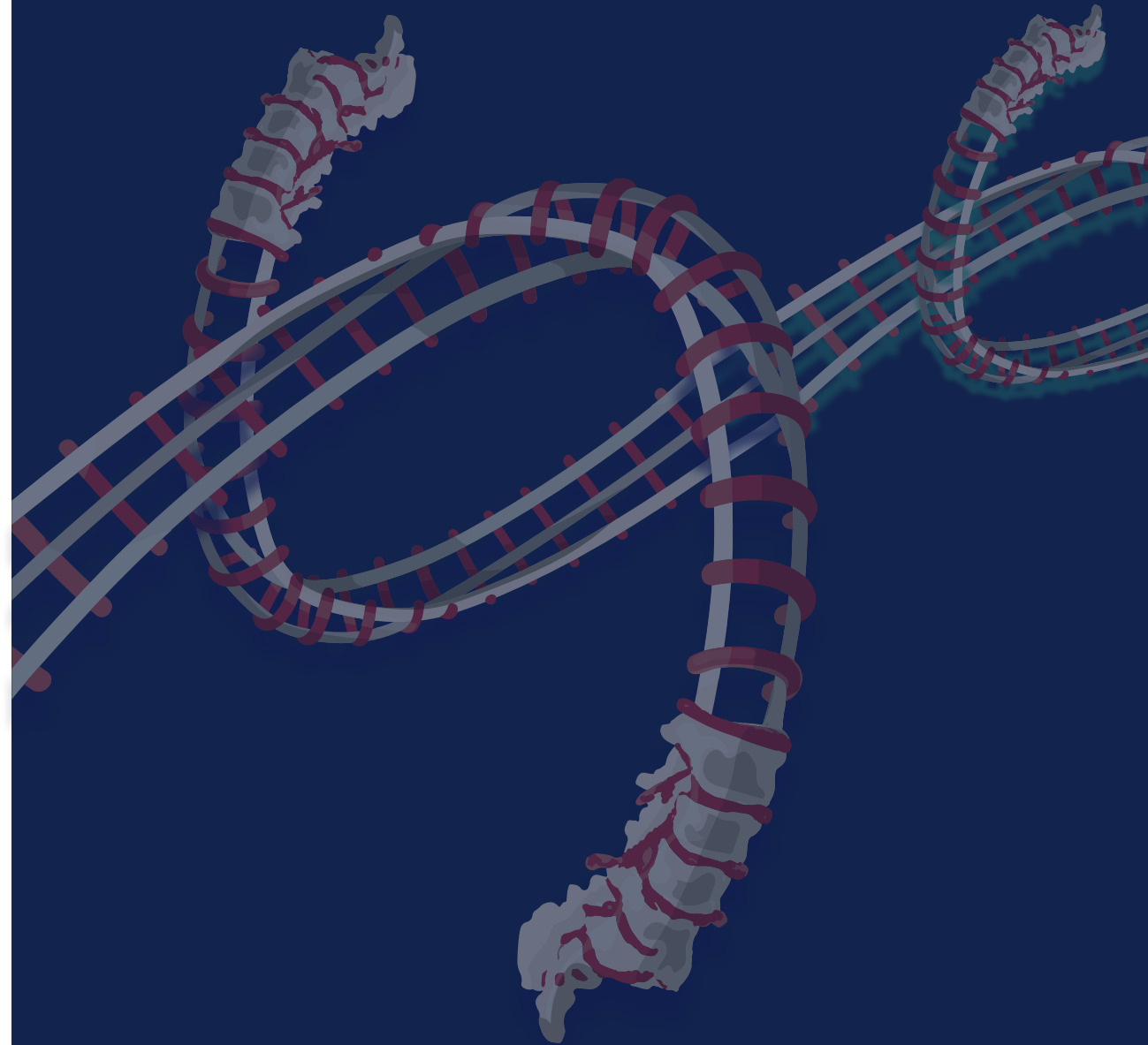
If you believe that this document breaches copyright please contact us providing details, and we will remove access to the work immediately and investigate your claim.

### **E-mail address:**

[vuresearchportal.ub@vu.nl](mailto:vuresearchportal.ub@vu.nl)

## Chapter 10

### General discussion



This thesis combines experimental and clinical studies on the surgical treatment of adolescent idiopathic scoliosis (AIS). A summary of the answers to the research questions posed in this thesis is presented below. Finally, the results are put into a broader perspective by discussing the implications for current and future surgical treatment of AIS.

## PART I

### I. What is the effect on intra-operative spinal flexibility of posterior spinal releases?

*Chapter 2* presents the results of a study in which sequential posterior releases on human cadaveric spinal specimens were performed and their effect on spinal flexibility was quantified using a spinal motion simulator [1]. The range of motion (ROM) was analysed in flexion, extension, lateral bending and axial rotation. The flexibility in spinal flexion and axial rotation increased significantly after removal of the supraand interspinous ligaments (10.2% and 3.1% respectively), inferior facets (4.1% and 7.7% respectively), and flaval ligament (9.1% and 2.5% respectively). A sequential superior facetectomy provided only some additional increase in flexion flexibility and not in the other planes of motion.

### II. What is the effect on the biomechanical properties of the human spine of a new embalming method, impacting our evaluation of new techniques for spinal surgery?

In the study presented in *Chapter 3* the new embalming method Fix for Life (F4L) was analysed [2]. F4L combines a lower formaldehyde concentration and components that aim to preserve the mechanical properties of the tissue. For this, fresh frozen human cadaveric spinal specimens were tested at baseline and after F4L embalming. The study showed that the embalming resulted in substantial increases in stiffness (up to 230%) relative to the fresh frozen conditions. Also, the average spinal ROM decreased by 46% in flexion-extension, 56% in lateral bending and 54% in axial rotation compared to baseline fresh frozen.

### III. What mechanisms do patients with AIS utilise during gait to compensate for the loss of spinal motion after spinal correction and fusion surgery?

*Chapters 4, 5* and *6* of thesis present the data of three studies that aim to clarify the role of the spine during gait in patients with AIS, and to investigate why

short-term postoperative effects such as decreased physical function and long-term effects such as adjacent segment degeneration can occur. In *Chapter 4* we performed a prospective study on gait analysis in AIS patients treated by posterior spinal correction and fusion (PSF) surgery [3]. In healthy subjects, walking at challenging (high) walking speeds causes an increased relative transversal plane motion between thorax and pelvis and an increased pelvis motion [4,5]. Also, cadence (i.e. steps/min), step length, and motion of the pelvis in the transverse plane increase at higher walking speeds [4,5]. This could pose a problem for AIS patients after PSF surgery, as the fusion limits the motion of the spine, which is the anatomical connection between the thorax and the pelvis. We hypothesized that scoliosis surgery would cause a decrease in transverse plane pelvis ROM and consequently a decrease in step length. Subsequently, to compensate for this loss in step length, we expected the cadence to increase to maintain walking speed. As hypothesized, the studies showed that the thoracic-pelvic and pelvis transverse plane ROM decreased after PSF. This effect was more explicit at higher walking speeds, indicating that the higher speeds elucidated the negative effect of surgery. In contrast to our hypothesis, the step length did not decrease and cadence actually showed a decrease at a constant and high gait speed. Similar to healthy subjects, AIS patients were able to increase step length to accommodate the higher walking speeds.

Because *Chapter 4* could not identify a compensatory mechanism in the lower extremities, we proceeded to analyse the upper body in more detail. In *Chapter 5* it was hypothesized that an increased motion of the unfused part of the spine compensates for the loss of motion of the fused spinal segments [6]. This would explain the relatively good physical function after surgery and the occurrence of adjacent segment degeneration due to increased stress on the intervertebral disc [7]. To investigate this, a detailed analysis on motions of trunk sections was performed in *Chapter 5*. This was, to the best of our knowledge, the first study to analyse separate trunk sections in surgically treated AIS patients during a dynamic activity such as gait. The transverse plane ROM of the fused and distally unfused spine showed an overall decrease of 29% at 3 months after PSF. Although of a nearly similar magnitude (26%), this decrease was no longer statistically significant 12 months after PSF. Instead of a compensatory increase, the caudal unfused spinal segments showed a decrease of 32% in ROM at 12 months after PSF. Hence, in contrast to the posed hypothesis, we could not identify a compensatory mechanism in the unfused spine in this

study. In comparison, other studies (based on maximum bending movements during stance) report conflicting results, with some reporting increases in distal adjacent segment motion [8,9] while others contradict this finding [10–14].

Building further on the knowledge gained in *Chapter 5*, we performed a more in-depth analysis of the relative motion between the shoulders and the thorax in *Chapter 6*. Thorax-pelvis counter-rotation in the transversal plane is required to limit body axial angular momentum and to thus limit energy expenditure [15,16]. Additionally, thorax-pelvis rotation shifts from a relatively in-phase motion at low walking speed to more out-of-phase at high walking speed in healthy subjects [17]. This counter-rotation is limited after PSF surgery for AIS, as was shown in *Chapter 5* and by others [3,10,13,18–20]. In *Chapter 6* we hypothesized that, in the transversal plane, the phase difference between shoulders and thorax increases after surgery to maintain the out-of-phase timing between the upper body and the pelvis at higher walking speeds. An additional increase in relative shoulders-thorax ROM was expected. The results of these studies showed that, in contrast to our hypotheses, neither the shoulder-thorax ROM, nor the shoulder-thorax phase difference increased after PSF surgery.

## PART II

### IV. What steps are needed when introducing a new medical technology into daily clinical practice?

Less invasive and fusionless scoliosis correction has the potential to overcome the negative effects associated to PSF surgery. Part II of this thesis analysed such a fusionless technique. In *Chapter 7* a case study is presented on the introduction of a new implant that was designed for the fusionless correction of AIS [21]. With the New Interventions in Clinical Practice guidebook (Nieuwe Interventies in de Klinische Praktijk, NIKP), all the important aspects of the introduction of a new technology were evaluated. An important step in this guidebook is the prospective risk analysis. For *Chapter 7* this analysis was performed in a multidisciplinary team consisting of orthopedic surgeons, a trauma surgeon, a clinical physicist, a researcher, a quality employee, the supplier, the manufacturer, a procurement employee, and the physiotherapists. The team identified multiple risks associated with the novel treatment (e.g. correct implant size not available, incorrect surgical technique or faulty

execution of postoperative physical exercises). For every identified risk of the new technology a mitigating action was proposed (e.g. training of the attending surgeon, guidance by a physical therapist, etc). With regards to the risk of implant breakage or dislodgement, the team decided that an additional biomechanical *in vitro* analysis of the implant had to be performed, of which the results are presented in *Chapter 8*. Based on those results and other insights acquired by following the NIKP guidebook, it was concluded that it was justified to further analyse the use of this new technique in a small prospective clinical study. The preliminary results of this study are presented in *Chapter 9*.

### V. How does a novel periapical concave distraction device for the fusionless correction of AIS affect spinal biomechanical properties?

In *Chapter 8* a novel posterior concave periapical distraction device was tested, which was designed to meet the need for a less invasive and fusionless technique for scoliosis surgery [22]. In traditional spinal fusion surgery, rigid implants are used to facilitate fusion of the corrected spine. Failure of these materials can occur if fusion is not achieved and spinal loads are transferred to the implant [23]. Thus, an implant used in fusionless scoliosis surgery should be designed to receive a minimal amount of forces. Therefore, before actual clinical evaluation, the new implant was tested on human and porcine fresh frozen cadaveric spines in a spinal motion simulator and compared to conventional rigid implants. The porcine spines were added to the analysis because human cadaveric spines are mostly from old donors, and porcine spines better represent the flexible adolescent spine [24,25]. The standard rigid instrumentation nearly completely diminished spinal ROM in flexion-extension (human -80.9% and porcine -94.0%), lateral bending (human -75.0% and porcine -92.2%), and axial rotation (human -71.3% and porcine -86.9%). It was hypothesized that the new periapical distraction device would not alter spinal motion due to its mobile connections. However, the results indicated that the periapical distraction device does decrease the average ROM in flexion-extension (human -40.0% and porcine -55.9%), while lateral bending was also slightly affected (human -18.2% and porcine -17.9%).

### VI. How effective and safe is the novel periapical concave distraction device for the fusionless surgical correction of AIS?

Based on the results presented in *Chapter 7* and *Chapter 8*, a clinical study was performed to analyse the safety and effectiveness of the periapical distraction device in skeletally immature AIS patients. *Chapter 9* presented the preliminary

results of this, at writing of this thesis still ongoing, prospective cohort study with currently 20 enrolled patients. The surgical parameters demonstrate the less-invasive characteristics of this new surgical technique; 5.6 levels were bridged in Lenke 1 curves and 4.2 levels in the Lenke 5 curves, surgery lasted 1 hour, blood loss was minimal, and the incision length was 16 cm. In contrast, in previous studies PSF surgery has been shown to result in approximately 10 fused levels in Lenke 1 curves and 6 levels in Lenke 5 curves, 4 hours surgical time, blood loss around 900 ml, and an incision length of 29 cm [26–29]. With the periapical concave distraction device the average major curve Cobb angle decreased from  $44.3 \pm 4.1^\circ$  pre-operatively to  $32.4 \pm 6.4^\circ$  in the Lenke 1 curves and from  $46.8^\circ \pm 5.2^\circ$  to  $32.3^\circ \pm 7.6^\circ$  in the Lenke 5 curves at final follow-up. In comparison, traditional PSF surgery decreases the Cobb angle to  $15\text{--}25^\circ$  [30–32]. During the postoperative follow-up period seven revision surgeries were performed due to complications. Nearly all complications were related to the implant, with the most prevalent being the occurrence of osteolysis around one of the pedicle screws. Malalignment of the pedicle screws in the sagittal plane, which limits the polyaxial motion of the screw-rod interface, was more prominent in the patients in whom revision surgery was required. In three out of five patients with osteolysis the cultures of the deep tissue taken during revision surgery showed infections with *Propionibacterium Acnes*. Lastly, screw breakage occurred in one patient. The total score on the SRS-22r patient reported outcome measure questionnaire significantly improved from  $2.5 \pm 0.3$  to  $4.2 \pm 0.6$ . Though, the postoperative SRS-22r score for those patients whom required revision surgery was not available yet at the time of writing.

## Implications

The technological advances in surgical strategies and implants of the past decades have significantly improved the treatment of the deformities associated with AIS [33]. Nowadays PSF surgery allows for a reliable correction of the lateral deviation, rotational deformity, and sagittal malalignment of the spine. As a result, the rib hump, waistline asymmetry, and shoulder height difference can be substantially corrected. Still, surgery has remained a highly invasive endeavour associated with prolonged surgical times, blood loss, and lengthy hospital stays. The fusion has a detrimental effect on the motion of the spine. It is associated with long-term complications such as adjacent segment degeneration, adding on, and proximal junctional kyphosis. Lastly, it leaves the patient with a long scar. This thesis aims to improve our understanding of the effect of spinal fusion surgery on biomechanics, while at the same time working towards a radical improvement by evaluating a new fusionless correction technique.

Posterior spinal releases are used to increase intra-operative spinal flexibility and thus facilitate the correction of the scoliotic deformity. Clinical studies on the effectiveness of spinal releases show contradictory results and biomechanical evidence is lacking [34–38]. Our biomechanical study demonstrated that in cadaveric spines the effect of posterior spinal releases on spinal flexibility decreased with each subsequent step. Thus, incremental posterior spinal releases follow the law of diminishing returns: increasing the removal of posterior spinal structures does not result in a linear increase of spinal flexibility. The study was limited by the use of non-scoliotic cadaveric spines from old human cadaveric donors without a full rib cage due to technological restrictions of the experimental setup. The effect of the spinal releases could be different in AIS patients due to altered anatomy and age effects. Also, Ponte et al. recently published an article appropriately titled ‘The True Ponte Osteotomy: By the One Who Developed It’ [39]. The authors correctly pointed out that the posterior releases illustrated in *Chapter 2* involved no removal of a part of the lamina and thus do not represent a full Ponte osteotomy. Indeed, removing bone from the lamina could potentially result in more flexibility. But, as the lamina is a bony structure located at the posterior side of the spine, its removal is only beneficial in increasing extension flexibility. Increased flexibility in extension is not needed in AIS surgery as these patients suffer from a hypokyphosis and gaining flexibility in flexion is

more important [40]. Hence, despite the discussion concerning partial or full laminectomy, we conclude that the routine use of full Ponte osteotomies in surgery for AIS patients with moderate curves can be questioned. Limiting the extent of the posterior releases can positively impact blood loss, operative time, and risk of nerve root damage [34,41].

This and other analyses of surgical techniques are often tested on so-called fresh frozen (i.e. not embalmed) human specimens. This poses a risk of infection to the worker and limits the time the specimens can be used for analyses before the tissues deteriorate. Embalming with formaldehyde can overcome these drawbacks, but by significantly altering the tissue stiffness this technique has a negative effect on spinal biomechanics [42]. The new F4L embalming method aims to preserve the biomechanical properties, potentially making it suitable for the analysis of surgical techniques [43]. Unfortunately this thesis shows that, in its current form, this embalming method is not valid for preclinical biomechanical testing of new surgical techniques. As the results are less detrimental than when using traditional formaldehyde embalming (which reduces the ROM by 80% in all loading directions), the technique can still be applied to provide residents and surgeons improved learning opportunities by providing a specimen that better represents natural tissue properties [42]. As other novel techniques also fail to fully preserve biomechanical tissue properties or have not yet been biomechanically tested the search for a suitable embalming technique continues [44,45].

In general, AIS patients recover relatively well after PSF surgery [30–32]. It is often hypothesized that increased motions in the unfused part of the spine occurs to compensate for the loss of motion at the levels of the fusion. This could play a role in the occurrence of long-term complications such as adjacent segment degeneration. In the short-term, it is surprising how relatively well the patients function in daily life after PSF surgery when the presumed key roles of the spine are considered (i.e. a shock absorber, an engine that drives the pelvis, and an important factor to reduce energy consumption) [50–52]. Possibly, mechanisms that compensate for the loss of spinal mobility after fusion explain both these observations. In this thesis three prospective gait analysis studies were performed to identify these possible changes in kinematic patterns that compensate for the local restriction of spinal motion after fusion. Surprisingly, this thesis could not identify the hypothesized compensatory mechanisms in the spatiotemporal parameters or lower body kinematics. Additionally, such

mechanisms were neither found in the distally unfused part of the spine (i.e. the kinematics between the fusion mass and the pelvis), nor at the proximal end (i.e. the kinematics between the shoulders and the spinal fusion mass). This contradicts the hypothesis that the increased rate of adjacent segment degeneration after spinal fusion occurs due to increased motion and stress on the non-fused spinal segments, as no such increases were identified.

Instead, the ROM during gait of both the fused and unfused part of the spine was diminished [6]. Possibly this is a mechanism to protect the unfused spinal segments from damage by excessive rotations. On the other hand, this could also negatively affect daily life, because surgically treated AIS patients with lower lumbar spine ROM report lower physical function scores and more time on sick leave due to back pain [46]. Moreover, the loss of spinal flexibility after PSF surgery is the most cited reason by patients for returning to a lower sport activity level or not returning to sport at all [47]. Overall, these findings could indicate a role for physical therapy to regain spinal ROM. However, prospective analyses of the effectiveness of physical rehabilitation programs is currently lacking [48,49].

The lack of finding compensatory mechanisms in the gait studies performed here is surprising. Maybe the spine is not so important for normal gait (in AIS patients) after all? The middle part of the thoracic spine already lacks substantial motion during gait in healthy individuals [53,54] and AIS itself induces another decrease in spinal mobility on top of this [55–57]. A stiff spine at baseline limits the effect of spinal fusion on spinal motion. Or perhaps each patient has a unique compensatory strategy, which is lost due to the averaging of the data across the study group? Additionally, patients could employ combinations of small compensatory mechanisms, which were not analysed in the current studies. Lastly, maybe the reduced counter-rotation in the upper body was compensated by mechanisms not measured with the current study protocol? With the absence of compensatory mechanisms in the upper body, angular momentum peaks during gait can increase. The increased angular momentum could simply result in higher rotational forces between the shoe and floor. Lastly, the increased angular momentum may have been compensated by larger arm swing, which was not analysed in this thesis.

It should be noted that the absence of compensatory mechanisms during gait does not imply that such mechanisms are also absent during other activities. For instance, other authors compared AIS patients 12 months after spinal fusion to controls during a stop-jump exercise to elucidate compensatory mechanisms [58]. They concluded that the increased motion of the lumbar spine and the synchronous movement of the lumbar spine with the lower half of the thoracic spine were a compensation to perform the stop-jump task at a similar level as the healthy controls. Therefore, long-term complications such as adjacent segment degeneration might be related to compensatory lumbar motions during other activities than gait.

Less-invasive and fusionless surgical correction of AIS could potentially overcome the downsides associated with PSF surgery such as blood loss, duration of surgery, long scar, decreased postoperative physical function, and long-term complications [59,60]. Previous studies tried to reduce surgical invasiveness of fusion based surgery. Examples are the use of an anterior thoracoscopic approach or, through a posterior approach, by using three separate incisions and the subsequent subcutaneous passage of the rods [61,62]. The thoracoscopic approach results in fewer fused levels and less blood loss, while incision length decreases with both techniques. Unfortunately both techniques result in a long surgical time [61,62]. Recently, a prospective study was performed in which AIS patients with a double major curve were treated with dual sequential short anterior spinal fusion (ASF) and compared to a group treated by regular PSF surgery [63]. An average of only 7.6 vertebrae were fused after ASF and 12 vertebrae after PSF. A significant downside was that the ASF group was required to undergo surgery twice. These findings highlight that, although we can somewhat decrease the surgical invasiveness of current fusion-based techniques, a fundamental switch to less-invasive non-fusion techniques could provide more substantial improvements in surgical parameters and preservation of spinal flexibility.

Fusionless scoliosis surgery requires major technological developments. Several remarks on such fundamental changes are therefore warranted. As technological advances can provide major improvements in healthcare quality, it is key for new innovations to be readily available to the patient, while at the same time limiting the risks associated to these novel technologies. Multiple examples in the past illustrate that novel treatments can pose serious healthcare risks, especially when the technique is immediately applied in daily

clinical practice, thereby exposing many patients to the risks [64–69]. To limit such risks, in this thesis a step-wise approach was applied to evaluate a novel device that was designed for fusionless scoliosis surgery.

Step one in our evaluation of the new periapical concave distraction device for fusionless scoliosis correction was a prospective risk analysis. Based on this evaluation, step two was an evaluation of the device in a biomechanical *in vitro* study. The periapical distraction device caused less direct postoperative decrease in ROM than rigid pedicle screw based instrumentation, thus possibly resulting in a more physiological spinal movement *in vivo*. This could lead to better postoperative physical activity and function. However, due to limited space in the testing machine, specimens with only the posterior part of the ribs were used. Removal of the rib cage results in 40-52% increase in ROM and therefore the negative effect of the novel device on *in vivo* biomechanics could be less [70,71]. Still, spinal ROM was limited (mainly in flexion-extension), indicating that forces from spinal movement could be transferred to the periapical distraction device. During the market approval process (i.e. CE marking) the implant was already tested to failure and demonstrated to be able to withstand higher forces and more loading cycles in comparison to regular pedicle screw based instrumentation (results not presented in this thesis). In total, the risk of implant failure was expected to be present but estimated to be low. Also, if implant failure would occur, regular PSF surgery could be performed as a salvage procedure.

The third and final step of our evaluation was a prospective clinical evaluation of the novel implant in a small group of AIS patients aged 12-17 years with a Lenke 1 or 5 curve and a flexible major curve Cobb angle measuring 40-55°. The preliminary results show that the results of the fusionless treatment with the novel device differ significantly from those of traditional PSF surgery. Duration of surgery, blood loss, number of spinal levels bridged, and length of incision were significantly less compared to PSF [26–29]. On the other hand, the postoperative Cobb angle of the major curve averaged 32°, while traditional PSF surgery results in a substantially better correction by reducing the Cobb angle to 15-25° [30–32]. This limited correction could negatively affect outcome, because a correlation between curve correction and cosmetic outcome has been reported [72], although others contradict this finding [73]. Contrarily, the smaller incision leads to a smaller scar and thus could have a positive influence on cosmetic outcome and patient satisfaction.

Despite a careful prospective risk analysis, a preclinical *in vitro* evaluation, and stringent inclusion criteria several serious adverse events occurred in the prospective clinical study. Most of these were related to the implant. The preliminary results suggest that strict attention must be paid to parallel alignment of the screws in the sagittal plane and screw size. Additionally, in three patients with osteolysis around a pedicle screw *Propionibacterium Acnes* bacteria were cultured from the tissue obtained during revision surgery. This pathogen is also found in prominent bursa tissue in revision surgery of bulky posterior rigid instrumentation using transverse connectors or the Dynesys dynamic stabilisation system [74–76]. Similarly, the periapical distraction device in its current form has prominent pedicle screws. A newer low profile version of the implant is now available and its effect on clinical outcome should be investigated. Still, the clinical implications of the cultures are not fully understood, as *P. Acnes* is commonly present in a normal skin microbiome. Additionally, the pathogen is also frequently discovered in intervertebral discs of patients undergoing microdiscectomy without previous spinal surgery [77]. Furthermore, because the implant negatively affects spinal flexibility, everyday activities can induce micromotions at the screw-bone interface causing osteolysis. Next, the pathogen could spread to the space between the screw and bone. Hence, instead of *P. Acnes* causing osteolysis of the bone around the screws, the positive tissue cultures could simply represent an already present subclinical infection. Lastly, wear of the implant and metallosis was observed in five patients. The clinical relevance of metal debris is not fully understood, especially not in spine surgery. Some reports on its occurrence in spine surgery hypothesize that the titanium particles could act as a stimulus for late-onset inflammatory or infectious complications or osteolysis [78,79].

Recently, Floman and colleagues also presented their results with the periapical concave distraction device in 27 patients at 2-year follow-up [80]. Similar to the patient cohort presented in this thesis, the average pre-operative Cobb angle was 44° (range 32–55°). Surgical parameters were not reported. The coronal deformity corrected to 29° (range 6–45°), which is comparable to the results presented here. Of the SRS-22 questionnaire only the self-image domain was reported, improving from  $3.1 \pm 0.5$  to  $3.7 \pm 0.4$ . One deep wound infection occurred at 1-year follow-up. No implant related failures were described. The latter is in sharp contrast to the results presented here. At present it remains unknown why the complication rates differ so much.

In very skeletally immature patients, anterior vertebral body tethering and stapling can be used to correct the deformity without spinal fusion. These techniques apply compressive forces on the convexity of the curve to reduce growth rate on the convexity of the curve. Two studies on skeletally immature patients demonstrated that tethering can result in correction rates to below 20° Cobb angle [81,82]. Compared to our experience with the periapical concave distraction, anterior tethering did not result in device related complications. Though, a downside of the tethering technique is the long duration of surgery (4–5 hours). Vertebral body stapling was also shown to be safer, although correction rates were not better than bracing therapy [83]. As such, these techniques appear to be safer than the posterior concave distraction device in its current form and tethering results in higher correction rates, although the follow-up period for both devices is still limited.

Overall, the periapical concave distraction appears to have several advantages: it requires only two anchor points, requires short duration of surgery, and results in minimal blood loss and a small scar. The shortcomings include reduced correction of the deformity compared to traditional surgical techniques and, most notably, the high complication rates in the patient cohort presented here. The effect on functional ROM and/or gait was not investigated in this thesis and is a subject for future work. At the time of writing the inclusion of new patients in the clinical study has been halted due to the high complication rate. The already treated patients will be carefully followed to shed more light on the causes of the observed complications. Doing so we can hopefully identify those patients at risk for complications and in the future only treat those patients who will benefit from this new technique.



## Conclusions

In this thesis conventional and novel surgical treatment techniques for adolescent idiopathic scoliosis were evaluated with the use of *in vitro* and *in vivo* studies.

Traditionally, outcome assessment of orthopaedic surgery was based on static radiological parameters. However, orthopaedic surgery involves the treatment of deformities that affect everyday dynamic tasks and activities of the patient. Therefore, an increasing emphasis has been put on patient reported outcome measures in the last decade. Although this has led to a major improvement in outcome assessment, the present thesis emphasizes the continuing need for basic science and functional outcome measurements. The gait analyses could not identify mechanisms that compensate for the loss of spinal flexibility after spinal fusion. Instead, posterior spinal fusion surgery resulted in an overall increased body symmetry while at the same time causing an overall decrease in motion. This identifies a possible role for physical rehabilitation programs and underlines the need for motion-preserving fusionless surgical techniques.

The novel posterior concave distraction device studied in this thesis proved unsuitable for fusionless correction of AIS in daily clinical practice in its current form due to high complication rates. Its application remains limited to the evaluation in clinical studies. Clearly, further analysis is needed and improvement in implant design and surgical technique could decrease complication rates. Hopefully, this and other techniques will bring us one step closer to better treatment options for patients suffering from AIS.

## References

- Holewijn RM, Schlösser TPC, Bisschop A, van der Veen AJ, Stadhouder A, Van Royen AJ, et al. How Does Spinal Release and Ponte Osteotomy Improve Spinal Flexibility? The Law of Diminishing Returns. *Spine Deform* 2015;3:489–95.
- Holewijn RM, Faraj SSA, Kingma I, Royen BJ Van, Kleuver M De, Veen AJ Van Der. Spinal biomechanical properties are significantly altered with a novel embalming method. *J Biomech* 2017;ePub.
- Holewijn RM, Kingma I, de Kleuver M, Schimmel JJP, Keijsers NLW. Spinal fusion limits upper body range of motion during gait without inducing compensatory mechanisms in adolescent idiopathic scoliosis patients. *Gait Posture* 2017;57:1–6.
- Yang Y-T, Yoshida Y, Hortobágyi T, Suzuki S. Interaction between thorax, lumbar, and pelvis movements in the transverse plane during gait at three velocities. *J Appl Biomech* 2013;29:261–9.
- Bruijn SM, Meijer OG, van Dieën JH, Kingma I, Lamothe CJC. Coordination of leg swing, thorax rotations, and pelvis rotations during gait: The organisation of total body angular momentum. *Gait Posture* 2008;27:455–62.
- Holewijn RM, Kingma I, de Kleuver M, Keijsers NLW. Posterior spinal surgery for adolescent idiopathic scoliosis does not induce compensatory increases in distal adjacent segment motion: a prospective gait analysis study. *Spine J* 2018:[Epub ahead of print].
- Zhang C, Berven SH, Fortin M, Weber MH. Adjacent Segment Degeneration Versus Disease After Lumbar Spine Fusion for Degenerative Pathology: A Systematic Review With Meta-Analysis of the Literature. *Clin Spine Surg* 2016;29:21–9.
- Marks M, Newton PO, Petcharaporn M, Bastrom TP, Shah S, Betz R, et al. Postoperative Segmental Motion of the Unfused Spine Distal to the Fusion in 100 Patients With Adolescent Idiopathic Scoliosis. *Spine (Phila Pa 1976)* 2012;37:826–32.
- Marks M, Bastrom T, Petcharaporn M, Shah S, Betz R, Samdani A, et al. The Effect of Time and Fusion Length on Motion of the Unfused Lumbar Segments in Adolescent Idiopathic Scoliosis. *Spine Deform* 2015;3:549–53.
- Lenke LG, Engsborg JR, Ross S a, Reitenbach A, Blanke K, Bridwell KH. Prospective dynamic functional evaluation of gait and spinal balance following spinal fusion in adolescent idiopathic scoliosis. *Spine (Phila Pa 1976)* 2001;26:E330-7.
- Hassani S, Graf A. Assessing Spinal Motion at Different Fusion Levels in Adolescents with Idiopathic Scoliosis. *Proc Gait Clin Mov Anal Soc* 2012;163–4.
- Skalli W, Zeller RD, Miladi L, Bourcureau G, Savidan M, Lavaste F, et al. Importance of pelvic compensation in posture and motion after posterior spinal fusion using CD instrumentation for idiopathic scoliosis. *Spine (Phila Pa 1976)* 2006;31:E359-66.
- Engsborg JR, Lenke LG, Reitenbach AK, Hollander KW, Bridwell KH, Blanke K. Prospective evaluation of trunk range of motion in adolescents with idiopathic scoliosis undergoing spinal fusion surgery. *Spine (Phila Pa 1976)* 2002;27:1346–54.
- Wilk B, Karol LA, Johnston CE, Colby S, Haideri N. The effect of scoliosis fusion on spinal motion: a comparison of fused and nonfused patients with idiopathic scoliosis. *Spine (Phila Pa 1976)* 2006;31:309–14.
- Lamothe CJC, Beek PJ, Meijer OG. Pelvis-thorax coordination in the transverse plane during gait. *Gait Posture* 2002;16:101–14.
- Whittle MW, Levine D. Three-dimensional relationships between the movements of the pelvis and lumbar spine during normal gait. *Hum Mov Sci* 1999;18:681–92.
- van Emmerik RE, Wagenaar RC. Effects of walking velocity on relative phase dynamics in the trunk in human walking. *J Biomech* 1996;29:1175–84.

18. Engsborg JR, Lenke LG, Uhrich ML, Ross SA, Bridwell KH. Prospective comparison of gait and trunk range of motion in adolescents with idiopathic thoracic scoliosis undergoing anterior or posterior spinal fusion. *Spine (Phila Pa 1976)* 2003;28:1993–2000.
19. Wong-Chung DACF, Schimmel JJP, de Kleuver M, Keijsers NLW. Asymmetrical trunk movement during walking improved to normal range at 3 months after corrective posterior spinal fusion in adolescent idiopathic scoliosis. *Eur Spine J* 2017.
20. Mahaudens P, Detrembleur C, Mousny M, Banse X. Gait in thoracolumbar/lumbar adolescent idiopathic scoliosis: Effect of surgery on gait mechanisms. *Eur Spine J* 2010;19:1179–88.
21. Holewijn RM, Stadhouders A, de Kleuver M. Nieuwe techniek introduceren? Weeg eerst de risico's. *Med Contact (Bussum)* 2018;36:42–4.
22. Holewijn RM, de Kleuver M, van der Veen AJ, Emanuel KS, Bisschop A, Stadhouders A, et al. A Novel Spinal Implant for Fusionless Scoliosis Correction: A Biomechanical Analysis of the Motion Preserving Properties of a Posterior Periapical Concave Distraction Device. *Glob Spine J* 2017;7:400–9.
23. Weiss H-R, Goodall D. Rate of complications in scoliosis surgery – a systematic review of the Pub Med literature. *Scoliosis* 2008;3:9.
24. Busscher I, Van Der Veen AJ, Van Dieen JH, Kingma I, Verkerke GJ, Veldhuizen AG. In vitro biomechanical characteristics of the spine: A comparison between human and porcine spinal segments. *Spine (Phila Pa 1976)* 2010;35:E35–42.
25. Wilke HJ, Geppert J, Kienle A. Biomechanical in vitro evaluation of the complete porcine spine in comparison with data of the human spine. *Eur Spine J* 2011;20:1859–68.
26. Newton PO, Marks MC, Bastrom TP, Betz R, Clements D, Lonner B, et al. Surgical treatment of Lenke 1 main thoracic idiopathic scoliosis: results of a prospective, multicenter study. *Spine (Phila Pa 1976)* 2013;38:328–38.
27. Abel MF, Singla A, Feger MA, Sauer LD, Novicoff W. Surgical treatment of Lenke 5 adolescent idiopathic scoliosis: Comparison of anterior vs posterior approach. *World J Orthop* 2016;7:553–60.
28. Ialenti MN, Lonner BS, Verma K, Dean L, Valdevit A, Errico T. Predicting Operative Blood Loss During Spinal Fusion for Adolescent Idiopathic Scoliosis. *J Pediatr Orthop* 2013;33:372–6.
29. Li C, Yang M, Wang C, Wang C, Fan J, Chen Z, et al. Preoperative Factors Predicting Intraoperative Blood Loss in Female Patients With Adolescent Idiopathic Scoliosis. *Medicine (Baltimore)* 2015;94:e359.
30. Suk S II, Lee SM, Chung ER, Kim JH, Kim SS. Selective thoracic fusion with segmental pedicle screw fixation in the treatment of thoracic idiopathic scoliosis: More than 5-year follow-up. *Spine (Phila Pa 1976)* 2005;30:1602–9.
31. Lehman RA, Lenke LG, Keeler KA, Kim YJ, Buchowski JM, Cheh G, et al. Operative treatment of adolescent idiopathic scoliosis with posterior pedicle screw-only constructs minimum three-year follow-up of one hundred fourteen cases. *Spine (Phila Pa 1976)* 2008;33:1598–604.
32. Min K, Sdzuy C, Farshad M. Posterior correction of thoracic adolescent idiopathic scoliosis with pedicle screw instrumentation: Results of 48 patients with minimal 10-year follow-up. *Eur Spine J* 2013;22:345–54.
33. Hasler CC. A brief overview of 100 years of history of surgical treatment for adolescent idiopathic scoliosis. *J Child Orthop* 2013;7:57–62.
34. Halanski MA, Cassidy J a. Do Multilevel Ponte Osteotomies in Thoracic Idiopathic Scoliosis Surgery Improve Curve Correction and Restore Thoracic Kyphosis? *J Spinal Disord Tech* 2013;26:1.
35. Koerner JD, Patel A, Zhao C, Schoenberg C, Mishra A, Vives MJ, et al. Blood loss during posterior spinal fusion for adolescent idiopathic scoliosis. *Spine (Phila Pa 1976)* 2014;39:1479–87.
36. Samdani AF, Bennett JT, Singla AR, Marks MC, Pahys JM, Lonner BS, et al. Do ponte osteotomies enhance correction in adolescent idiopathic scoliosis? An analysis of 191 lenke 1A and 1B curves. *Spine Deform* 2015;3:483–8.
37. Takahashi J, Ikegami S, Kuraishi S. Skip pedicle screw fixation combined with Ponte osteotomy for adolescent idiopathic scoliosis. *Eur Spine* 2014;23:2689–95.
38. Kleuver M De, Lewis SJ, Germscheid NM, Kamper SJ, de Kleuver M, Lewis SJ, et al. Optimal surgical care for adolescent idiopathic scoliosis : an international consensus. *Eur Spine J* 2014;23:2603–18.
39. Ponte A, Orlando G, Siccardi GL. The True Ponte Osteotomy: By the One Who Developed It. *Spine Deform* 2018;6:2–11.
40. Schlösser TPC, Van Stralen M, Chu WCW, Lam TP, Ng BKW, Vincken KL, et al. Anterior overgrowth in primary curves, compensatory curves and junctional segments in adolescent idiopathic scoliosis. *PLoS One* 2016;11:1–11.
41. Wahlquist S, Wongworawat M, Nelson S. When Does Intraoperative Blood Loss Occur During Pediatric Scoliosis Correction? *Spine Deform* 2017;5:387–91.
42. Wilke HJ, Krischak S, Claes LE. Formalin fixation strongly influences biomechanical properties of the spine. *J Biomech* 1996;29:1629–31.
43. van Dam AJ, van Munsteren JC, DeRuiter MC. Fix for Life: The Development of a New Embalming and Fixation Method to Preserve Life-like Morphology. *Annu. Meet. Soc. Preserv. Nat. Hist. Collect.*, 2014.
44. Wilke HJ, Werner K, Häussler K, Reinehr M, Böckers TM. Thiel-fixation preserves the non-linear load-deformation characteristic of spinal motion segments, but increases their flexibility. *J Mech Behav Biomed Mater* 2011;4:2133–7.
45. Betz RR, Antonacci MD, Cuddihy LA. Alternatives to spinal fusion surgery in pediatric deformity. *Spine (Phila Pa 1976)* 2018;29:430–5.
46. Danielsson AJ, Romberg K, Nachemson AL. Spinal range of motion, muscle endurance, and back pain and function at least 20 years after fusion or brace treatment for adolescent idiopathic scoliosis: A case-control study. *Spine (Phila Pa 1976)* 2006;31:275–83.
47. Fabricant PD, Admoni S har, Green DW, Ipp LS, Widmann RF. Return to athletic activity after posterior spinal fusion for adolescent idiopathic scoliosis: analysis of independent predictors. *J Pediatr Orthop* 2012;32:259–65.
48. Singh Kakar R, Simpson KJ, Das BM, Brown CN. Review of Physical Activity Benefits and Potential Considerations for Individuals with Surgical Fusion of Spine for Scoliosis. *Int J Exerc Sci* 2017;10:166–77.
49. Daryabor A, Arazpour M, Golchin N. Efficacy of Corrective Surgery for Gait and Energy Expenditure in Patients with Scoliosis: A Literature Review. *Asian Spine J* 2018;12:951–65.
50. Gracovetsky SA, Iacono S. Energy transfers in the spinal engine. *J Biomed Eng* 1987;9:99–114.
51. Gracovetsky S. An hypothesis for the role of the spine in human locomotion: A challenge to current thinking. *J Biomed Eng* 1985;7:205–16.
52. Capozzo A. Analysis of the linear displacement of the head and trunk during walking at different speeds. *J Biomech* 1981;14:411–25.
53. Syczewska MB, Öberg T, Karlsson D. Segmental movements of the spine during treadmill walking with normal speed. *Clin Biomech* 1999;14:384–8.
54. Wilke H-J, Herkommer A, Werner K, Liebsch C. In vitro analysis of the segmental flexibility of the thoracic spine 2017.
55. Kruger KM, Garman CMR, Krzak JJ, Graf A, Hassani S, Tarima S, et al. Effects of Spinal Fusion for Idiopathic Scoliosis on Lower Body Kinematics During Gait. *Spine Deform* 2018;6:441–7.
56. Poussa M, Mellin G. Spinal mobility and posture in adolescent idiopathic scoliosis at three stages of curve magnitude. *Spine (Phila Pa 1976)* 1992;17:757–60.
57. Poussa M, Härkönen H, Mellin G. Spinal mobility in adolescent girls with idiopathic scoliosis and in structurally normal controls. *Spine (Phila Pa 1976)* 1989;14:217–9.
58. Kakar RS, Li Y, Brown CN, Kim SH, Oswald TS, Simpson KJ. Spine kinematics exhibited during the stop-jump by physically active individuals with adolescent idiopathic scoliosis and spinal fusion. *Spine J* 2017.

59. Aronsson DD, Stokes IAF. Nonfusion treatment of adolescent idiopathic scoliosis by growth modulation and remodeling. *J Pediatr Orthop* 2011;31:599–106.
60. Liu J-M, Shen J-X. Advances in nonfusion techniques for the treatment of scoliosis in children. *Orthop Surg* 2010;2:254–9.
61. Padhye K, Soroceanu A, Russell D, El-Hawary R. Thoracoscopic Anterior Instrumentation and Fusion as a Treatment for Adolescent Idiopathic Scoliosis: A Systematic Review of the Literature. *Spine Deform* 2018;6:384–90.
62. Sarwahi V, Wollowick AL, Sugarman EP, Horn JJ, Gambassi M, Amaral TD. Minimally invasive scoliosis surgery: An innovative technique in patients with adolescent idiopathic scoliosis. *Scoliosis* 2011;6:16.
63. Min K, Jud L, Farshad M. Dual Sequential Short Anterior Correction in Double Major Adolescent Idiopathic Scoliosis. *Spine Deform* 2018;6:545–51.
64. Lawsuit Settled Over Heart Valve Implicated in About 300 Deaths *The New York Times* 1992.
65. van der Graaf Y, de Waard F, van Herwerden LA, Defauw J. Risk of strut fracture of Björk-Shiley valves. *Lancet (London, England)* 1992;339:257–61.
66. Martindale V, Menache A. The PIP scandal: an analysis of the process of quality control that failed to safeguard women from the health risks. *J R Soc Med* 2013;106:173–7.
67. <https://www.orthopeden.org/kwaliteit/kwaliteitsbeleid/mom-heuprothese.n.d>.
68. Cohen D. How safe are metal-on-metal hip implants? *BMJ* 2012;344:e1410.
69. Rosenberg E, Berkhout K. Patiënten wisten niet dat ze proefkonijnen waren. *NRC Handelsblad*. 2016.
70. Liebsch C, Graf M, Appelt K, Wilke H-J. The rib cage stabilizes the human thoracic spine: An in vitro study using stepwise reduction of rib cage structures 2017.
71. Watkins IV R, Watkins R, Williams L, Ahlbrand S, Garcia R, Karamanian A, et al. Stability provided by the sternum and rib cage in the thoracic spine. *Spine (Phila Pa 1976)* 2005;30:1283–6.
72. Ghandehari H, Mahabadi MA, Mahdavi SSM, Shahsavaripour A, Seyed Tari HV, Safdari F, et al. Evaluation of Patient Outcome and Satisfaction after Surgical Treatment of Adolescent Idiopathic Scoliosis Using Scoliosis Research Society-30. *Arch Bone Jt Surg* 2015;3:109–13.
73. Izatt MT, Adam CJ, Labrom RD, Askin GN. The relationship between deformity correction and clinical outcomes after thoracoscopic scoliosis surgery: A prospective series of one hundred patients. *Spine (Phila Pa 1976)* 2010;35:E1577–85.
74. Richards BS, Emara KM. Delayed infections after posterior TSRH spinal instrumentation for idiopathic scoliosis: Revisited. *Spine (Phila Pa 1976)* 2001;26:1990–6.
75. Hahn F, Zbinden R, Min K. Late implant infections caused by *Propionibacterium acnes* in scoliosis surgery. *Eur Spine J* 2005;14:783–8.
76. Lutz JA, Otten P, Maestretti G. Late infections after dynamic stabilization of the lumbar spine with Dynesys. *Eur Spine J* 2012;21:2573–9.
77. Capoor MN, Ruzicka F, Schmitz JE, James GA, Machackova T, Jancalek R, et al. *Propionibacterium acnes* biofilm is present in intervertebral discs of patients undergoing microdiscectomy. *PLoS One* 2017;12:e0174518.
78. Cunningham BW, Orbegoso CM, Dmitriev AE, Hallab NJ, Seftor JC, McAfee PC. The effect of titanium particulate on development and maintenance of a posterolateral spinal arthrodesis: an in vivo rabbit model. *Spine (Phila Pa 1976)* 2002;27:1971–81.
79. Shang X, Wang L, Kou D, Jia X, Yang X, Zhang M, et al. Metal hypersensitivity in patient with posterior lumbar spine fusion: a case report and its literature review. *BMC Musculoskelet Disord* 2014;15:314.
80. Floman Y, Gavrilu S, Pataczek T, Zarzycki D, Desai B, Sekouris N, et al. A new posterior dynamic device for correction of moderate adolescent idiopathic scoliosis: 27 cases with over two years of follow-up (proceedings of the 2018 EUROSPINE meeting). *Eur Spine J* 2018;27:P101.
81. Samdani AF, Ames RJ, Kimball JS, Pahys JM, Grewal H, Pelletier GJ, et al. Anterior vertebral body tethering for immature adolescent idiopathic scoliosis: one-year results on the first 32 patients. *Eur Spine J* 2014;24:1533–9.
82. Perkins C, Moideen AN, Sashin A. Return to activity and sports following posterior correction and fusion for adolescent idiopathic scoliosis (proceedings of the 2017 Annual Meeting of the British Scoliosis Society). *Spine J* 2017;17:S329–30.
83. Cuddihy L, Danielsson AJ, Cahill PJ, Samdani AF, Grewal H, Richmond JM, et al. Vertebral Body Stapling versus Bracing for Patients with High-Risk Moderate Idiopathic Scoliosis. *Biomed Res Int* 2015;2015.