

VU Research Portal

Advanced Imaging in Glioma Treatment

Verburg, N.

2020

document version

Publisher's PDF, also known as Version of record

[Link to publication in VU Research Portal](#)

citation for published version (APA)

Verburg, N. (2020). *Advanced Imaging in Glioma Treatment: Moving the Frontier*. [PhD-Thesis - Research and graduation internal, Vrije Universiteit Amsterdam].

General rights

Copyright and moral rights for the publications made accessible in the public portal are retained by the authors and/or other copyright owners and it is a condition of accessing publications that users recognise and abide by the legal requirements associated with these rights.

- Users may download and print one copy of any publication from the public portal for the purpose of private study or research.
- You may not further distribute the material or use it for any profit-making activity or commercial gain
- You may freely distribute the URL identifying the publication in the public portal

Take down policy

If you believe that this document breaches copyright please contact us providing details, and we will remove access to the work immediately and investigate your claim.

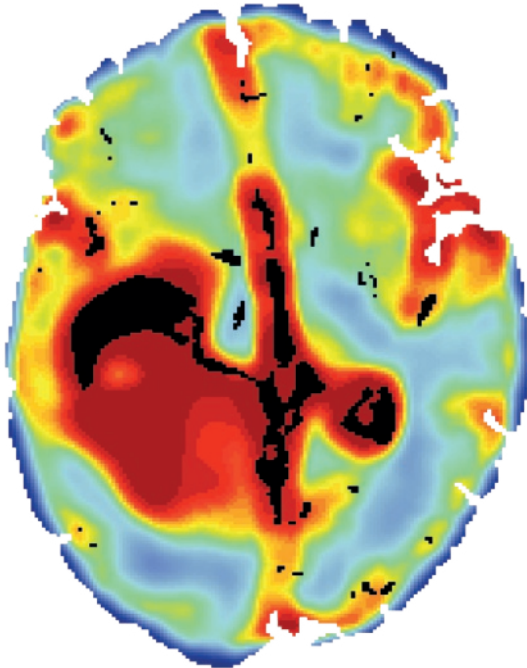
E-mail address:

vuresearchportal.ub@vu.nl

Chapter

11

Discussion



This thesis set out to answer the following question: “Which MRI sequence, PET tracer, or combination of MRI sequence(s) and/or PET tracer(s) is the most accurate for the detection of diffuse glioma infiltration?”. In order to answer this question, multiple studies were undertaken. First, the available literature for imaging accuracy was reviewed and the accuracy the biopsy technique used in later studies was determined. Next, kinetic modeling and construction of parametric maps of [¹⁸F]FET PET were investigated. Additionally, two PET tracers were directly compared and a diagnostic accuracy study was conducted to compare multiple MRI sequences, PET tracers and combinations of MRI sequence(s) and/or PET tracer(s) for the detection of glioma infiltration. Finally, diffuse glioma infiltration was quantified and molecular intratumoral heterogeneity explored.

This general discussion concerns the overarching themes of the previous chapters and is followed by future perspectives of advanced imaging in the treatment of patients with a glioma.

GENERAL DISCUSSION

Current standard radiological imaging for the detection of diffuse glioma infiltration

There is no unambiguous standard imaging protocol for the detection of diffuse glioma infiltration. Recently, consensus recommendations for brain tumor imaging have suggested the following MRI sequences: T1w, T2w, FLAIR, T1G and DWI.³⁸ These recommendations reflect the historically grown custom of T1G for enhancing and T2w and/or FLAIR for non-enhancing gliomas. Unfortunately, these standard MRI sequences are not the most accurate for the detection of diffuse glioma infiltration, as was concluded from the meta-analysis in chapter 2 and the prospective diagnostic accuracy study in chapter 9.

It must be noted that there is a difference in standard MRI accuracy for detection of diffuse glioma infiltration in enhancing versus non-enhancing gliomas, with a considerably lower accuracy in enhancing gliomas. For T1G MRI, a suggested cause for this lower accuracy is the correlation between cellularity and T1G signal.³¹⁵ This prevents detection of glioma cells in areas with lower cellularity, resulting in a lower sensitivity. For T2 and FLAIR MRI, the abnormal signal depends on edema, myelin loss and other damage to central nervous system tissue.⁷⁰ Since tumor cells are not always present

in areas with edema in glioma patients,^{3,64,71,352} specificity of these sequences is lower. Besides the lower accuracy of standard MRI for the detection of glioma infiltration, direct comparison with other MRI sequences or imaging modalities in the clinical setting is sparse or even missing. T1G MRI-guided glioma resection has only been compared, in a non-randomized setting, with image-guided resection based on FLAIR MRI, MRSI CNI and amino acid PET.^{7,79,129} T2- and FLAIR-guided surgery in non-enhancing glioma has never been compared with other MRI sequences or imaging modalities. Furthermore, T1G MRI-guided resection of enhancing gliomas results in considerable residual glioma infiltration in areas without contrast enhancement. This thesis shows that the molecular profile of this residual glioma infiltration is identical to the resected tumor core and not a 'low-grade component',^{45,353} underlining the necessity to expand surgical resections beyond T1G abnormalities.

These findings demonstrate the overall lack of evidence for the use of the current standard MRI protocol for the guidance of local treatment in glioma. The Response Assessment in Neuro-Oncology (RANO) working group recommendations have recently concluded that amino acid PET is superior to standard MRI for the delineation of all diffuse gliomas.⁸³ This thesis underlines the value of amino acid PET, implying that amino acid PET should be included in the current standard imaging protocol for glioma.

The use of amino acid PET as a new standard for imaging of gliomas raises the question which type of PET-derived image, as well as scan interval, should be used. Multiple image types can be derived from PET: standardized uptake value (SUV), tumor-to-brain ratio (TBR) and different quantitative parametric maps. TBR was the most frequently used image in the studies on which the RANO recommendations as well as the European Association of Nuclear Medicine (EANM) guideline were based.^{83,354} The advantage of TBR over SUV is the lower variability in tumor uptake, making it more suitable for inter-individual comparison,²⁷⁰ as also confirmed in chapter 8. Quantitative parametric maps are images based on a tracer kinetic model and have been sparsely investigated for glioma imaging. A reversible two-tissue compartment model was found to be the most accurate for [¹⁸F]FET uptake in glioma, and since TBR maps do not require dynamic acquisition and arterial input function, we concluded that TBR maps should be used, which is in line with the current literature.^{83,354}

The optimal scan interval for amino acid PET is more clearly defined, with the EANM guideline recommending a 40-minute (min) scan with images from the 20–40 min

interval.³⁵⁴ Although multiple chapters in this thesis found the 60–90min interval superior to the 20–40min, our main results were in line with the EANM recommendation of the 20–40min interval. The contradicting results in this thesis can be attributed to the subset of patients used in chapters 6–8, compared to the main results in chapter 9.

Imaging combinations for the detection of diffuse glioma infiltration

Both the consensus brain tumor imaging protocol and RANO recommendations propose a single MRI sequence or PET tracer for the delineation of gliomas.^{38,83} Combinations of MRI sequence(s) and/or PET tracer(s), from now on referred to as “imaging combinations”, could, however, potentially be more accurate than a single MRI sequence or PET tracer. This is acknowledged in the RANO recommendations, which suggested future studies with combinations of MRI and PET. In this thesis multiple MRI sequences and the amino acid tracer [¹⁸F]FET PET were compared, as well as combined, for the detection of glioma infiltration, resulting in a combination of Apparent Diffusion Coefficient (ADC) MRI and [¹⁸F]FET PET (ADC/FET) to be more accurate in the detection of glioma infiltration in enhancing gliomas than the current standard MRI and single amino acid PET. The results of this unique study, due to the total number of samples and the acquisition of samples from regions without imaging abnormalities, are comparable with the few other studies that have addressed imaging combinations. These studies all found combinations more accurate than single MRI sequences or PET tracers for the detection of extent of glioma infiltration.^{54,311-316} This is also in line with studies applying imaging combinations for other clinical problems in glioma such as biopsy targeting,³⁵⁰ tumor grading,^{355,356} radionecrosis,³⁵⁷ and IDH-mutation status.³⁵⁸ Furthermore, imaging combinations are not only more accurate in glioma, but also in other types of cancer such as prostate,³⁵⁹ breast,³⁶⁰ and colorectal cancer.³⁶¹ This demonstrates the overall value of imaging combinations, which join the strengths of individual techniques, while overcoming their limitations.

Imaging combinations requires clinicians to evaluate imaging in a different fashion. Currently, most neurosurgeons delineate the glioma by visual inspection of imaging abnormalities on one MRI sequence, although some may include a second MRI sequence in case of an enhancing glioma. This qualitative method of delineation is subject to high inter- and even intra-observer variability.^{141,362} When applying qualitative delineation to imaging combinations another problem occurs: how to define the delineation on multiple MRI sequences and/or PET images? One could delineate a glioma on each MRI sequence or PET image separately and then combine the delineations into one. However, if each

the MRI sequence of PET image in itself is insufficient to visualize the glioma infiltration, the combination might not perform better than the single MRI sequence of PET image. Quantitative imaging analysis can overcome both the observer variability and difficulty of tumor delineation on imaging combinations. Quantitative imaging analysis is based on numeric voxel values in images and allows for multiple mathematical techniques to summarize these values. Using the Receiver Operating Characteristics (ROC) method an optimal threshold can be calculated. This threshold is a numeric value that can be applied to images, resulting in binary images consisting of voxels below or above the threshold. Therefore, observer variability does not exist in quantitative imaging analysis since a numeric threshold replaces the observer. The difficulty of tumor delineation on imaging combinations is solved by combining the different MRI sequence(s) and/or PET image(s) into one. These combined images are based on the voxel values of each MRI sequence(s) and/or PET image(s) and a formula for the combining. These voxel combinations could result in a value above the optimal threshold, even though none of voxel values of the single MRI sequence(s) and/or PET image(s) was above the threshold.

Although quantitative imaging analysis overcomes the major shortcoming of qualitative imaging assessment, limitations do exist. The main limitation is the external validation. Since most imaging combinations are derived from a single imaging protocol, typically acquired on one or two scanners, absolute numeric thresholds might not be applicable to other imaging protocols and/or scanners. This would obstruct the implementation of imaging combinations outside the initiators' environment. A possible solution for this problem is the use of normalized values in imaging techniques with relative measurements. Multiple normalization methods are available,³⁶³ mostly based on a region of interest (ROI) in a part of the brain that is not affected by the disease. By dividing MRI sequences or PET images by the mean values of the ROI of the normal brain all voxel values become a ratio, instead of a relative value. These ratios are recommended by the European Association of Nuclear Medicine since they allow intra- and inter-patient comparison.³⁶³ Besides external validation, limitations include the technical challenges of multimodality fusion and computational processing, as well as imaging artifacts due to the quantitative thresholds like described in chapter 9.

Quantification of diffuse glioma infiltration

There is no 'gold standard' for the quantification of diffuse glioma infiltration. Assessment of the presence of tumor cells by a neuropathologist remains the 'gold standard'. In daily practice, samples sent for diagnosis are mostly from the core of the tumor.

Assessment of the presence of tumor cells in samples from the periphery of a tumor with little to no tumor infiltration however, is limited by the fact that single neoplastic glial tumor cells frequently cannot be distinguished from normal or reactive cells on grounds of morphology or immunocytochemical profile alone.²⁸ This was reflected by the moderate interobserver agreement between the two neuropathologists. Interestingly, the interobserver agreement was found to be higher in non-enhancing than in enhancing gliomas. This is most likely due to the more peripheral localization of samples in enhancing gliomas, which was less possible in non-enhancing gliomas due to the eloquence of the surrounding brain. Identification of tumor presence can benefit from immunohisto-chemistry for IDH1 R132H mutant protein. Yet, it was not used in this thesis since it would have introduced a bias between the assessment of IDH-mutant and IDH-wildtype gliomas. A limitation of the neuropathologist's assessment in this thesis was the binary outcome of tumor presence, or not. Since glioma infiltration percentages decline with distance to the tumor core,³⁶⁴ much information is lost by this binarization.

Currently, histological metrics are usually applied for quantification of glioma infiltration, so-called tumor purity, with the Ki-67 index and cellularity most commonly used. We found both histological metrics less accurate, leading to an underestimation of tumor purity, compared to a DNA methylation-based metric, which is in conformity with a recent meta-analysis using different modalities for tumor purity measurement in >10.000 samples in 21 cancer types.³⁴⁶ Possible cause for this lower accuracy is the low specificity of both cellularity, which can also be higher in reactive brain tissue,³⁶⁵ and Ki-67 index, which is also higher in inflammatory and microglial cells.³⁴⁸ Also, migrating glioma cells demonstrate lower proliferation rates and therefore a lower Ki-67 index.²⁶ This in contrast to the DNA methylation-based metric, PAMES (Purity Assessment from clonal MEhylation Sites),³⁴⁵ that is based on tumor-specific molecular characteristics resulting in a high sensitivity and specificity. Therefore, tumor presence was detected using PAMES in samples with low cellularity, low Ki-67 index, or both, and vice versa, implying that PAMES is superior the current histological metrics for the quantification of diffuse glioma infiltration,

FUTURE PERSPECTIVES

A new standard imaging protocol for glioma

Based on the findings in this thesis a new imaging protocol for the detection of glioma infiltration in both enhancing and non-enhancing gliomas should be implemented. A minimum protocol should include dynamic 40 minutes [^{18}F]FET PET, DTI and FLAIR MRI, while 3D T1G is solely included for the neuronavigation and visualization of vascular structures. Not using T1G MRI for glioma delineation and grading will be quite a paradigm shift however, supported by the lower accuracy of T1G MRI for the detection of glioma infiltration in enhancing gliomas than both single [^{18}F]FET and the ADC/FET combination in this thesis, and the lower accuracy of T1G MRI for glioma grading compared to dynamic [^{18}F]FET PET in the literature.^{39,307} The [^{18}F]FET PET is necessary to obtain the 20–40 minute tumor-to-brain ratio map that is combined with the DTI ADC to generate the ADC/FET probability map. For the 30% of low-grade gliomas that are [^{18}F]FET negative, FLAIR MRI can be used to guide local treatment. The use of DTI to generate the ADC map, instead of DWI, also allows for the visualization of white-matter tracts with DTI tractography, which results in higher resection percentages, better clinical condition and longer OS.¹⁷³

Local treatment beyond standard MRI abnormalities

With this new imaging protocol, local treatment could be guided beyond standard MRI abnormalities. Although evidence is sparse,³⁶⁶ resections beyond T1G MRI abnormalities in enhancing gliomas appear to improve patients' outcome.^{7,79,129} These studies were based on resections guided by respectively FLAIR MRI, MRSI and amino acid PET, which were all less accurate than the ADC/FET combination. Therefore, translating the results of these studies to ADC/FET, improvement of patients' outcome is to be expected of ADC/FET-guided resections. Another argument to expand the resection of enhancing gliomas beyond the T1G abnormalities is the similarity of the molecular profile of peripheral and core glioma regions. The difference between regions with and without enhancement in enhancing gliomas could therefore be attributed to the tumor purity, rather than intratumoral heterogeneity. This implies that glioma in peripheral regions is as aggressive as in the core only in lower quantities. As demonstrated in chapter 10, the tumor purity slowly declines in enhancing gliomas, with a higher tumor purity directly outside the enhancement region compared to regions further from the enhancement region. This explains that in 80–90% of patients glioma recurs adjacent to the resection cavity.^{5,6} Although not proven, the higher accuracy of ADC/FET most likely implies that

this combination can also visualize regions with a lower tumor purity, allowing for a better estimation of the total glioma infiltration.

Individualized treatment using probability maps for tumor presence

Besides the superior accuracy, ADC/FET-imaging has the potential to support individualized local treatments. The ADC/FET probability maps represent the probability of tumor presence (0 to 1) for each voxel. Assuming that this tumor probability is an estimation of the actual tumor purity, a probability can be used as threshold to guide resection and/or radiotherapy. A lower probability threshold will result in a larger tumor volume and vice versa. The choice of probability threshold will depend on age, clinical condition, eloquence of surrounding brain and patient's preference. For example, a young patient with a right frontal glioma will allow for a low probability threshold, while a high probability will be used for an older patient with a left fronto-parietal tumor. This method is only feasible if neuromonitoring is incorporated into the surgical strategy, since regions with lower probability, compared to regions with a higher probability, are more likely to include important brain functions in white matter tracts due to the presence of more normal brain tissue. Although imaging techniques are helpful in surgical planning, awake or non-awake intra-operative mapping are the current standard for neuromonitoring. Some propose that glioma resections should be neuromonitoring-guided instead of imaging-guided.²⁰⁰ Translating this neuromonitoring-guided strategy into a diagnostic accuracy results in a high sensitivity with little residual tumor, however, also in a low specificity, since not all resected tissue will contain glioma infiltration. That not all resected tissue will contain tumor is doubted by those who see glioma as a 'whole brain disease'.³⁰ Yet, in this thesis glioma infiltration was not present in every sample, and even not in every sample from regions with imaging abnormalities. This is confirmed by post-mortem studies, with only 20% of patients demonstrating spread more than 3cm beyond the gross tumor,³⁶⁷ and infiltration not further than 12mm outside the core, defined as the area with 100–60% infiltration.³⁶⁸ This implies that glioma could be considered as a localized disease, although widespread in many patients, instead of a multi-focal 'whole brain disease'. Therefore, glioma should be treated with a combined image- and neuromonitoring-guided surgical strategy.

Future research

The above-mentioned perspectives require future research to prove their value for glioma treatment. First and foremost, a randomized clinical trial (RCT) is needed to compare image-guided local treatment of enhancing gliomas based on current standard

MRI versus ADC/FET. An improved progression free and/or overall survival in the ADC/FET arm is expected due to the more extensive resection. For an estimation of the effect of an extensive resection data from the largest study of extensive resections in glioblastoma could be used. In this study, OS improved from a median 15.5 to 20.7 months in patients with an extensive resection.⁷ This 33.5% gain could be an overestimation due to the retrospective nature of the study, so a 25% gain in OS would be a safer estimation. Calculating the sample size with the 25% gain in OS, a mean OS of 22.5(SD 18.4) months,³⁶⁹ an alpha of 0.05 and 80% power results in 173 patients for each arm, so 346 patients in total. This would require a European or international study, since about 390 patients per year undergo a resection for glioblastoma in the Netherlands.³⁷⁰ Although this will be a considerable challenge, willingness to participate in the study could be considerable since the ADC/FET probability map will allow each surgeon to choose their own target tumor volume for each individual patient and use neuromonitoring if they think it is necessary. This freedom in surgical strategy might overcome the reluctance, reflected by the single registered RCT for extensive resection in glioma assessed on August 2, 2019 at www.clinicaltrials.gov), to participate in a study investigating resections beyond standard MRI abnormalities in glioma surgery.

In this thesis an ADC/FET probability map for tumor presence was developed, based on the binary histopathological assessment of tumor presence by neuropathologists. This probability map assumes that the probability of tumor presence reflects tumor purity, with higher probabilities representing higher tumor purity and vice versa. This assumption however, is contradicted by the results of the assessment of tumor purity in this thesis. With a wide range of tumor purities, based on PAMES, in both samples assessed as tumor and normal, tumor probability and tumor purity might not correlate as well as assumed. Therefore, the probability map should be replaced by a tumor purity map that is based on the prediction of PAMES assessed tumor purity by combinations of imaging. Such a tumor purity map could be very similar to the probability map, yet with different scale. Next to a conceptual improvement, such as study would also serve as validation of the accuracy of ADC/FET combination.

In order to implement the ADC/FET probability or tumor purity map in daily practice, the problem of intra-operative brain shift needs to be addressed. Since brain shift up to 15 mm occurs during glioma resection,^{145,146} the pre-operatively obtained ADC/FET map needs to be updated during the procedure. Although an intraoperative MRI could facilitate this update, widespread implementation is limited due to its very high costs.

Intraoperative ultrasound is a cheaper and faster alternative for the intraoperative update of pre-operative imaging. Although much progress has been made, brain shift correction with ultrasound needs validation in larger patient cohorts before it can be used in daily practice.⁸¹ An additional possibility of ultrasound is the detection of glioma infiltration, which was highly accurate in the meta-analysis in this thesis (chapter 2). In order to visualize glioma infiltration, the ultrasound probe needs to be directly positioned on the brain. Therefore, ultrasound was not included in the study protocol (chapter 5) in this thesis. Still, ultrasound should be compared with ADC/FET for the detection of glioma infiltration. This could be achieved by assessment of the ADC/FET resection cavity walls with ultrasound. These cavity walls would ideally be the borders of the ADC/FET abnormalities if the resection was not limited by intraoperative monitoring. Ultrasound could possibly detect cavity walls regions suspicious for tumor that are to be sampled in order to compare diagnostic accuracy. Such a study could possibly even be combined with the above-mentioned RCT.

CONCLUSION

The combination of ADC MRI and [¹⁸F]FET PET is more accurate for the detection of glioma infiltration in enhancing glioma than current standard MRI. Next to the improved diagnostic accuracy, the probability map generated by this combination allows for a less or more extended resection that will facilitate individualized local treatment. If future studies confirm the assumed clinical value of ADC/FET-guided resections, ADC/FET could become the new standard imaging for local treatment in enhancing glioma.

